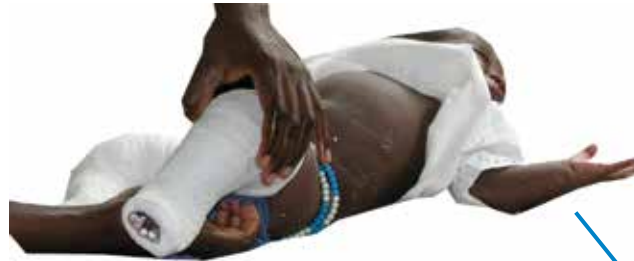
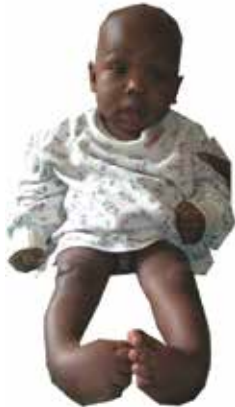
Clubfoot: Ponseti Management

Third Edition



Contents

Preface and Contributors	2
Translators	3
Scientific Basis of Management	4
Current Ponseti Management	6
Clubfoot Assessment	8
Ponseti Cast Correction	9
Common Management Errors	13
Tenotomy	14
Bracing	16
Increasing Brace Compliance.	18
Cultural Barriers to Management	19
Clubfoot Relapse	20
Atypical Clubfoot.	22

Reference

Anterior Tibialis Tendon Transfer	24
Brace Manufacture	26
Clubfoot Scoring	27
Information for Parents.	28
Bibliography	31
Global HELP Organization	32

Lynn Staheli, MD



GLOBAL HELP
HEALTH EDUCATION USING LOW-COST PUBLICATIONS

Preface

This is the third edition of the Global HELP Organization – sponsored Ponseti manual. In 2004 we published the first English versions in print and PDF formats (global-help.org). About 20,000 full color printed copies in 5 languages have been distributed in over 100 countries. Over 100,000 downloads of the PDF edition in 12 languages have been made from over 150 countries. Our new program provides this publication as part of a library of 26 books, articles and posters on a single compact disc. This CD library will make access convenient and more widely available, especially to countries with limited or absent web access.

This new edition was prepared to update content, facilitate translation, make more multicultural, and expand access. We added refinements in techniques such as showing the effectiveness of Ponseti management in older infants and children and difficult clubfoot. To make translations simpler, we provided a single larger space for the text of each page.

I wish to thank the contributors for helpful suggestions. I appreciate the permission from Dr. Pirani to include elements of our Uganda book in this publication, making this edition more comprehensive and multicultural. I thank Dr. Morcuende for his thoughtful review and contributions making the content of this new edition consistent with current Ponseti management from Iowa. I also appreciate Helen Schinske who donated her text-editing skills and the McCallum Print Group for printing this edition at a discounted price.

We are pleased to participate in making Ponseti management the standard of practice throughout the world.

We appreciate those who have translated this material into other languages, improving access to the material in many countries.

We always appreciate your feedback and suggestions.

Lynn Staheli, MD
Founder & Volunteer Director
Global HELP Organization
2009



GLOBAL HELP

The Global HELP organization provides free health-care information to developing countries and helping to make medical knowledge accessible worldwide. See www.global-help.org

Contributors

Ignacio Ponseti, MD

Dr. Ponseti developed his method of management more than 50 years ago and has treated hundreds of infants using this method. Currently Professor Emeritus at the University of Iowa, he provided guidance throughout the production of the book and wrote scientific basis of management.



Jose A. Morcuende, MD, PhD

A colleague of Dr. Ponseti, Dr. Morcuende provided the text for management and advice throughout the process of preparing the material for production.



Shafique Pirani, MD

A major contributor skilled in Ponseti management, Dr. Pirani is an advocate and early user of the method in Canada. He has created a successful model for using Ponseti management in undeveloped countries.



Vincent Mosca, MD

Dr. Mosca provided the section on information for parents and demonstrated the anterior tibialis transfer procedure.



Norgrove Penny, MD

Dr. Penny is a major contributor to the Uganda project. He has made many contributions for healthcare delivery in developing countries.



Fred Dietz, MD

A colleague of Dr. Ponseti, Dr. Dietz contributed the images and text for the management section.



John E. Herzenberg, MD

One of the first physicians to adopt the Ponseti method of clubfoot management outside of Iowa, Dr. Herzenberg contributed the text and illustrations for the sections on bracing and management of relapses.



Stuart Weinstein, MD

A long-term colleague of Dr. Ponseti and early advocate of his management, Dr. Weinstein contributed suggestions and support.



Michiel Steenbeek

Mr. Steenbeek is an orthotist and physiotherapist who designed a brace that is constructed using widely available tools and materials, making it useful in developing countries.



Translators

This booklet has been translated into additional languages by the following contributors:

Arabic

Dr. Alaa Azmi Ahma
Pediatric Orthopaedic Surgeon
Arab Care Hospital, Ramallah
Nables Speciality Hospital, Nables
Ramallah, The West Bank, Palestine



Dr. Ayman H. Jawadi
Assistant Professor, Consultant
Pediatric Orthopedic Surgery
King Saud Bin Abdulaziz University
for Health Science
King Abdulaziz Medical City
Riyadh, Saudi Arabia



Dr. Said Saghie
Assistant Professor
Orthopedic Surgery
American University of Beirut
Beirut, Lebanon



Chinese

Dr. Jack Cheng
Hong Kong, China
jackcheng@cuhk.edu.hk
Christian and Brian Trower
Guilin, China
trower@myrealbox.com



French

Dr. Franck Launay
Marseille, France
franck.launay@mail.ap-hm.fr



Italian

Dr. Gaetano Pagnotta
Rome, Italy
pagnotta@opbg.net



Japanese

Natsuo Yasui, Tokushima, Japan
nyasui@clin.med.tokushima-u.ac.jp
Hirohiko Yasui, Osaka, Japan
hirohiko_yasui@yahoo.co.jp
Yukihiko Yasui, Osaka, Japan
hikobosy@yahoo.co.jp



Polish

Dr. Marek Napiontek
Poznan, Poland
ortop@webmedia.pl



Portuguese

Dr. Monica Paschoal Nogueira
Sao Paulo, Brazil
monipn@uol.com.br



Russian and Ukrainian

Jolanta Kavaliauskiene
Kaunas, Lithuania
jokved@hotmail.com



Spanish

Dr. Jose Morcuende and
Helena Ponseti
Iowa City, Iowa, USA
jose-morcuende@uiowa.edu



Turkish

Dr. Selim Yalcin
Istanbul, Turkey
selimyalcin@ultrav.net



Vietnamese

Dr. Thanh Van Do
Danang city, Vietnam.
ctohcmvn@hcm.fpt.vn



Underway

Danish

Klaus Hindsø
hindso@dadlnet.dk

Finnish

Salminen Sari
sari.salminen@hus.fi

Georgian

Maia Gabunia
maianeuro@yahoo.com

German

Marc Sinclair
marc.sinclair@dbaj.ae

Persian / Farsi

Ali Khosrowabady
alirezak2002@yahoo.com
Emal Bardak
emalpgi@gmail.com

Swedish

Bertil Romanus
bromanus@yahoo.com

Urdu [Pakistan]

Asif Ali
asifop@yahoo.com

Considering

Indonesian

Timor Leste/Tetum

David McNicol

Scientific Basis of Management

Our treatment of clubfoot is based on the biology of the deformity and of the functional anatomy of the foot.

Biology

Clubfoot is not an embryonic malformation. A normally developing foot turns into a clubfoot during the second trimester of pregnancy. Clubfoot is rarely detected with ultrasonography before the 16th week of gestation. Therefore, like developmental hip dysplasia and idiopathic scoliosis, clubfoot is a developmental deformation.

A 17-week-old male fetus with bilateral clubfoot, more severe on the left, is shown [1]. A section in the frontal plane through the malleoli of the right clubfoot [2] shows the deltoid, tibionavicular ligament, and the tibialis posterior tendon to be very thick and to merge with the short plantar calcaneonavicular ligament. The interosseous talocalcaneal ligament is normal.

A photomicrograph of the tibionavicular ligament [3] shows the collagen fibers to be wavy and densely packed. The cells are very abundant, and many have spherical nuclei (original magnification, x475).

The shape of the tarsal joints is altered relative to the altered positions of the tarsal bones. The forefoot is in some pronation, causing the plantar arch to be more concave (cavus). Increasing flexion of the metatarsal bones is present in a lateromedial direction.

In the clubfoot, there appears to be excessive pull of the tibialis posterior abetted by the gastrosoleus and the long toe flexors. These muscles are smaller in size and shorter than in the normal foot. In the distal end of the gastrosoleus, there is an increase of connective tissue rich in collagen, which tends to spread into the tendo Achillis and the deep fasciae.

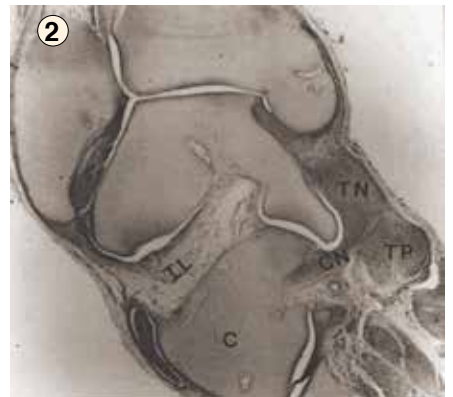
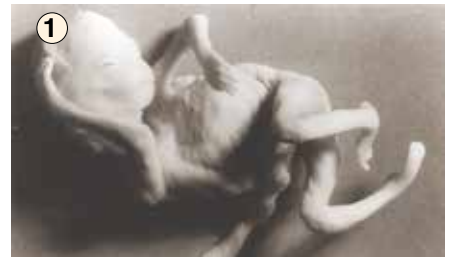In the clubfoot, the ligaments of the posterior and medial aspect of the ankle and tarsal joints are very thick and taut, thereby severely restraining the foot in equinus and the navicular and calcaneus in adduction and inversion. The size of the leg muscles correlates inversely with the severity of the deformity. In the most severe clubfoot, the gastrosoleus is seen as a muscle of small size in the upper third of the calf. Excessive collagen synthesis in the ligaments, tendons, and muscles may persist until the child is 3 or 4 years of age and might be a cause of relapses.

Under the microscope, the bundles of collagen fibers display a wavy appearance known as crimp. This crimp allows the ligaments to be stretched. Gentle stretching of the ligaments in the infant causes no harm. The crimp reappears a few days later, allowing for further stretching. That is why manual correction of the deformity is feasible.

Kinematics

The clubfoot deformity occurs mostly in the tarsus. The tarsal bones, which are mostly made of cartilage, are in the most extreme positions of flexion, adduction, and inversion at birth. The talus is in severe plantar flexion, its neck is medially and plantarly deflected, and its head is wedge-shaped. The navicular is severely medially displaced, close to the medial malleolus, and articulates with the medial surface of the head of the talus. The calcaneus is adducted and inverted under the talus.

As shown in a 3-day-old infant [4 opposite page], the navicular is medially displaced and articulates only with the medial aspect of the head of the talus. The cuneiforms are seen to the right of the navicular, and the cuboid is underneath it. The calcaneocuboid joint is directed posteromedially. The anterior two-thirds of the calcaneus is seen underneath the talus. The tendons of the tibialis anterior, extensor hallucis longus, and extensor digitorum longus are medially displaced.



No single axis of motion (like a mitered hinge) exists on which to rotate the tarsus, whether in a normal or a clubfoot. The tarsal joints are functionally interdependent. The movement of each tarsal bone involves simultaneous shifts in the adjacent bones. Joint motions are determined by the curvature of the joint surfaces and by the orientation and structure of the binding ligaments. Each joint has its own specific motion pattern. Therefore, correction of the extreme medial displacement and inversion of the tarsal bones in the clubfoot necessitates a simultaneous gradual lateral shift of the navicular, cuboid, and calcaneus before they can be everted into a neutral position. These displacements are feasible because the taut tarsal ligaments can be gradually stretched.

The correction of the severe displacements of the tarsal bones in clubfoot requires a clear understanding of the functional anatomy of the tarsus. Unfortunately, most orthopaedists treating clubfoot act on the wrong assumption that the subtalar and Chopart joints have a fixed axis of rotation that runs obliquely from anteromedial superior to posterolateral inferior, passing through the sinus tarsi. They believe that by pronating the foot on this axis, the heel varus and foot supination can be corrected. This is not so.

Pronating the clubfoot on this imaginary fixed axis tilts the forefoot into further pronation, thereby increasing the cavus and pressing the adducted calcaneus against the talus. The result is a breach in the hindfoot, leaving the heel varus uncorrected.

In the clubfoot [1], the anterior portion of the calcaneus lies beneath the head of the talus. This position causes varus and equinus deformity of the heel. Attempts to push the calcaneus into eversion without abducting it [2] will press the calcaneus against the talus and will not correct the heel varus. Lateral displacement (abduction) of the calcaneus to its normal relationship with the talus [3] will correct the heel varus deformity of the clubfoot.

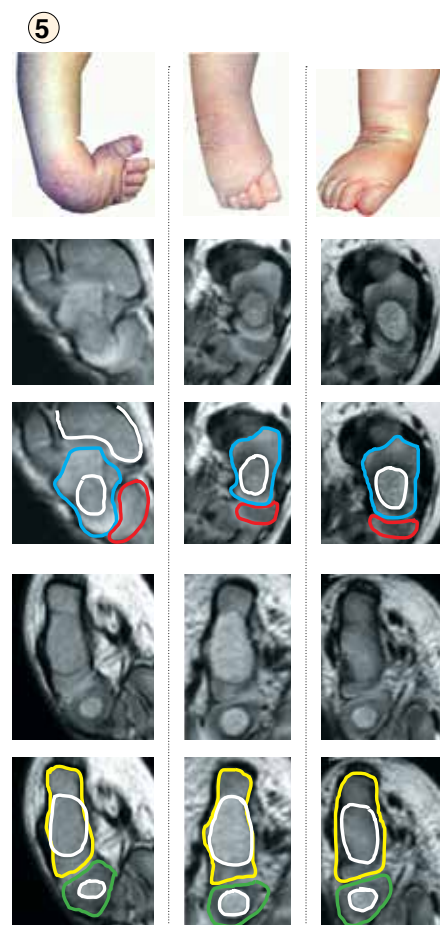
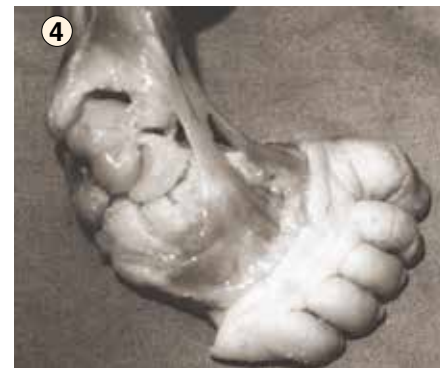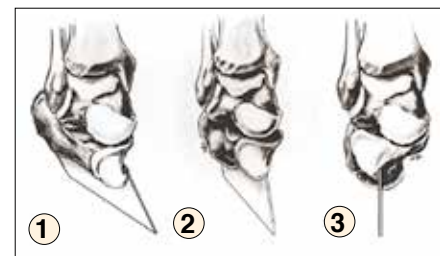
Correction of clubfoot is accomplished by abducting the foot in supination while counterpressure is applied over the lateral aspect of the head of the talus to prevent rotation of the talus in the ankle. A well-molded plaster cast maintains the foot in an improved position. The ligaments should never be stretched beyond their natural amount of give. After 5 days, the ligaments can be stretched again to further improve the degree of correction of the deformity.

The bones and joints remodel with each cast change because of the inherent properties of young connective tissue, cartilage, and bone, which respond to the changes in the direction of mechanical stimuli. This has been beautifully demonstrated by Pirani [5], comparing the clinical and magnetic resonance imaging appearance before, during, and at the end of cast treatment. Note the changes in the talonavicular joint and calcaneocuboid joint. Before treatment, the navicular (red outline) is displaced to the medial side of the head of the talus (blue). Note how this relationship normalizes during cast treatment. Similarly, the cuboid (green) becomes aligned with the calcaneus (yellow) during the same cast treatment.

Before applying the last plaster cast, the tendo Achillis may have to be percutaneously sectioned to achieve complete correction of the equinus. The tendo Achillis, unlike the tarsal ligaments that are stretchable, is made of non-stretchable, thick, tight collagen bundles with few cells. The last cast is left in place for 3 weeks while the severed heel-cord tendon regenerates in the proper length with minimal scarring. At that point, the tarsal joints have remodeled in the corrected positions.

In summary, most cases of clubfoot are corrected after five to six cast changes and, in many cases, a tendo Achillis tenotomy. This technique results in feet that are strong, flexible, and plantigrade. Maintenance of function without pain has been demonstrated in a 35-year follow-up study.

I. Ponseti, 2008



Current Ponseti Management

Is Ponseti management now accepted as optimal treatment worldwide?

Over the past decade Ponseti management has become accepted throughout the world [1] as the most effective and least expensive treatment of clubfoot.

How does Ponseti management correct the deformity?

Keep in mind the basic clubfoot deformity. Compare the normal relationships of the tarsal bones [2 left] with that of the clubfoot [2 right]. Note that the talus (red) is deformed and the navicular (yellow) is medially displaced. The foot is rotated around the head of the talus (blue arrow). Ponseti correction is achieved by reversing this rotation [3]. Correction is achieved gradually by serial casts. The Ponseti technique corrects the deformity by gradually rotating the foot around the head of the talus (red circle) over a period of weeks during cast correction.

When should treatment with Ponseti management be undertaken?

When possible, start soon after birth (7 to 10 days). However, most clubfoot deformities can be corrected throughout childhood using this management.

When treatment is started early, how many cast changes are usually required?

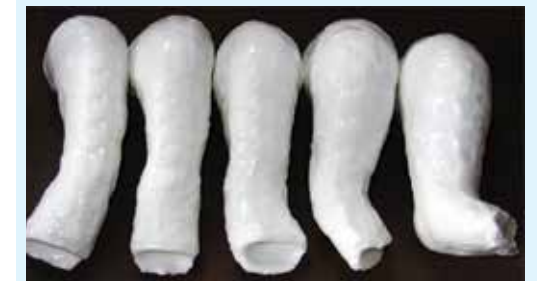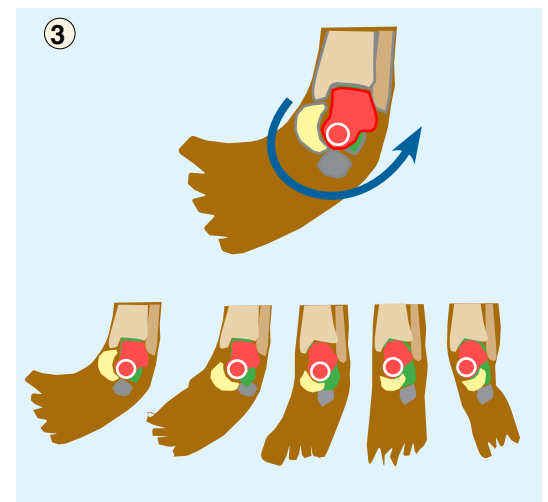
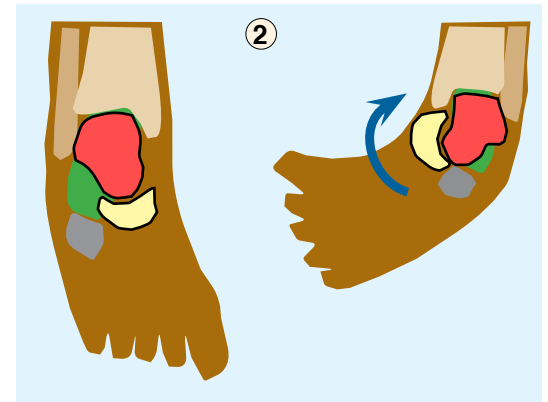
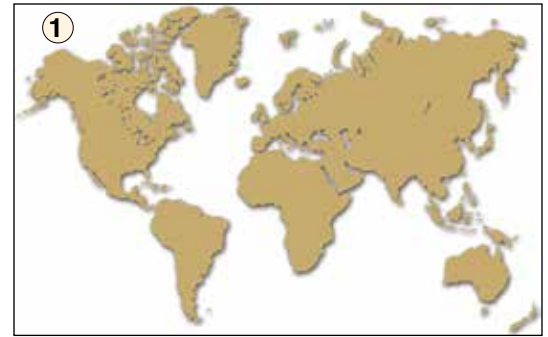Most clubfoot deformities can be corrected in approximately 6 weeks by weekly manipulations followed by plaster cast applications. If the deformity is not corrected after six or seven plaster cast changes, the treatment is most likely faulty.

How late can treatment be started and still be helpful?

The goal is to start treatment in the first few weeks after birth. However, correction can be achieved in many cases until late childhood.

Is Ponseti management useful if treatment is delayed?

Management that is delayed until early childhood may be started with Ponseti casts. In some cases, operative correction will be required, but the magnitude of the procedure may be less than would have been necessary without Ponseti management.



What is the expected outcome for the infant with clubfoot treated by Ponseti management?

In all patients with unilateral clubfoot, the affected foot is slightly shorter (mean, 1.3 cm) and narrower (mean, 0.4 cm) than the normal foot. The limb lengths, on the other hand, are the same, but the circumference of the leg on the affected side is smaller (mean, 2.3 cm). The foot should be strong, flexible, and pain free. This correction is expected throughout the person's lifetime. This provides the opportunity for normal function during childhood [1] and a pain-free and mobile foot during adult life.

What is the incidence of clubfoot in children with one or two parents who also are affected?

When one parent is affected with clubfoot, there is a 3% to 4% chance that the offspring will also be affected. However, when both parents are affected, the offspring have a 30% chance of developing clubfoot.

How do the outcomes of surgery and Ponseti management compare?

Surgery improves the initial appearance of the foot but does not prevent recurrence. Adult foot and ankle surgeons report that these surgically treated feet become weak, stiff, and often painful in adult life.

How often does Ponseti management fail and operative correction become necessary?

The success rate depends on the degree of stiffness of the foot, the experience of the surgeon, and the reliability of the family. In most situations, the success rate can be expected to exceed 95%. Failure is most likely if the foot is stiff with a deep crease on the sole of the foot and above the ankle, severe cavus and small gastrosoleus muscle with fibrosis of the lower half.

Is Ponseti management useful for clubfoot in infants with other musculoskeletal problems?


Ponseti management is appropriate for use in children with arthrogryposis, myelomeningocele, Larsen syndrome and other syndromes. Treatment is more difficult as correction takes longer and special care must be given in infants with sensory problems as in myelodysplasia to prevent skin ulcers.

Is Ponseti management useful for clubfoot previously treated by other methods?

Ponseti management is also successful when applied to feet that have been manipulated and casted by other practitioners who are not yet skilled in this very exacting management.

What are the usual steps of clubfoot management?

Most clubfoot can be corrected by brief manipulation and then casting in maximum correction. After approximately five casting periods, the cavus, adductus and varus are corrected. A percutaneous heel-cord tenotomy is performed in nearly all feet to complete the correction of the equinus, and the foot is placed in the last cast for 3 weeks. This correction is maintained by night splinting using a foot abduction brace [2], which is continued until approximately 2 to 4 years of age. Feet treated by this management have been shown to be strong, flexible, and pain free, allowing a normal life.



Clubfoot Assessment

Making the diagnosis

Screening Encourage all healthcare workers [1] to screen all newborns and infants for foot deformities [2] and other problems [3]. Infants with problems can be referred for care at a clubfoot clinic.

Confirming The diagnosis suggested during screening is made by someone with experience with musculoskeletal problems who can establish the diagnosis. The essential features of a clubfoot include cavus, varus, adductus and equinus [4].

During this evaluation, other conditions such as metatarsus adductus and the presence of some underlying syndrome can be ruled out. Furthermore, the clubfoot is classified into categories. This classification is made to establish the prognosis and to plan management.

Classifying the clubfoot

The classification of a clubfoot may change with time depending on management. .

Typical clubfoot

This is the classic clubfoot and is found in otherwise normal infants. It generally corrects in five casts, and with Ponseti management the long-term outcome is usually good or excellent.

Positional clubfoot Rarely the deformity is very flexible and is thought to be due to intrauterine crowding. Correction is often achieved with one or two castings.

Delayed treated clubfoot beyond 6 months of age.

Recurrent typical clubfoot may occur whether the original treatment was by Ponseti management or other methods. Relapse is much less frequent after Ponseti management and is usually due to a premature discontinuation of bracing. The recurrence is most often supination and equinus that is first dynamic but may become fixed with time.

Alternatively treated typical clubfoot includes feet treated by surgery or non-Ponseti casting.

Atypical clubfoot

This category of clubfoot is usually associated with other problems. Start with Ponseti management. Correction usually is more difficult.

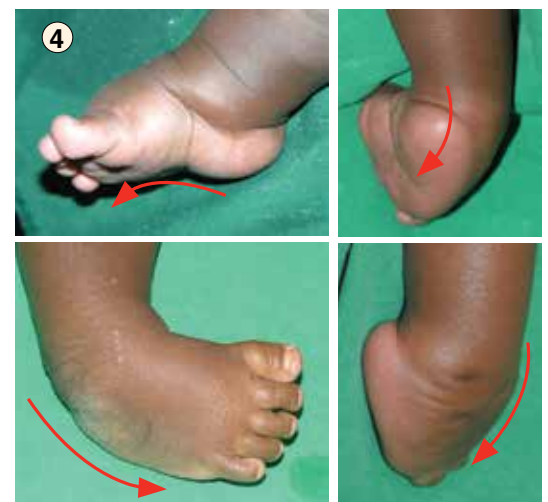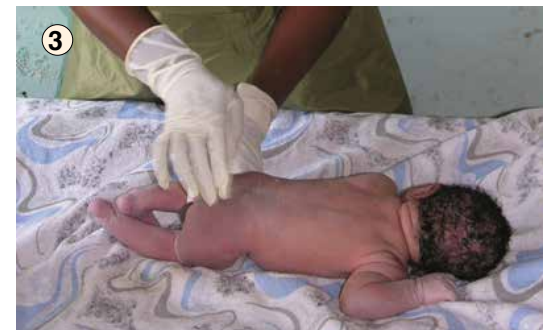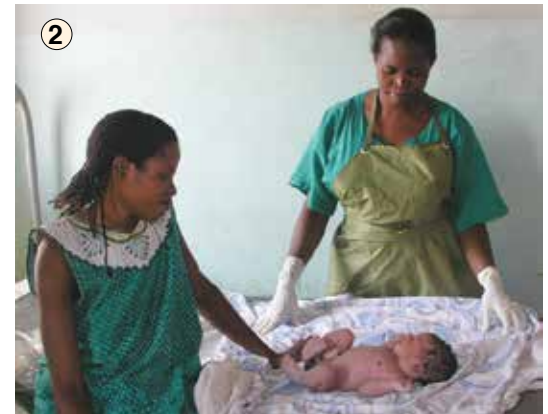Rigid or resistant atypical clubfoot may be thin or fat. The fat feet are much more difficult to treat. They are stiff, short, chubby, with a deep crease in the sole of the foot and behind the ankle, and have shortening of the first metatarsal with hyperextension of the metatarsal phalangeal joint (page 22). This deformity occurs in the otherwise normal infant.

Syndromic clubfoot Other congenital abnormalities are present (page 23). The clubfoot is part of a syndrome. Ponseti management remains the standard of care, but may be more difficult, and response may be less predictable. The final outcome may depend more on the underlying condition than the clubfoot.

Teratologic clubfoot – such as congenital tarsal synchondrosis.

Neurogenic clubfoot – associated with a neurological disorder such as meningomyelocele.

Acquired clubfoot – such as Streeter dysplasia.



Ponseti Cast Correction

Setup

The setup for casting includes calming the child with a bottle [1] or breast feeding. When possible have a trained assistant. Sometimes is necessary for the parent to assist. The treatment setup is important [2]. The assistant (blue dot) holds the foot while the manipulator (red dot) performs the correction.

Manipulation and casting

Start as soon after birth as possible. Make the infant and family comfortable. Allow the infant to feed during the manipulation and casting processes.

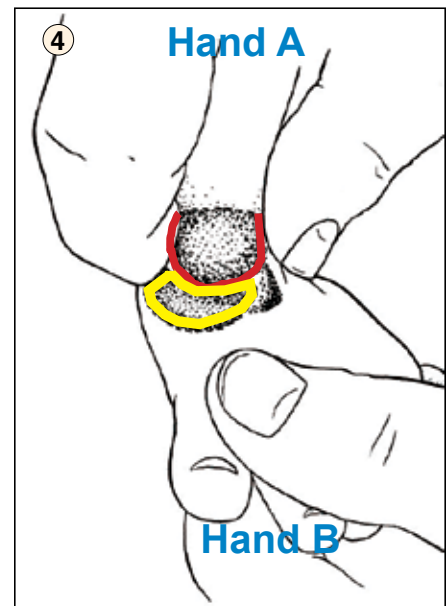
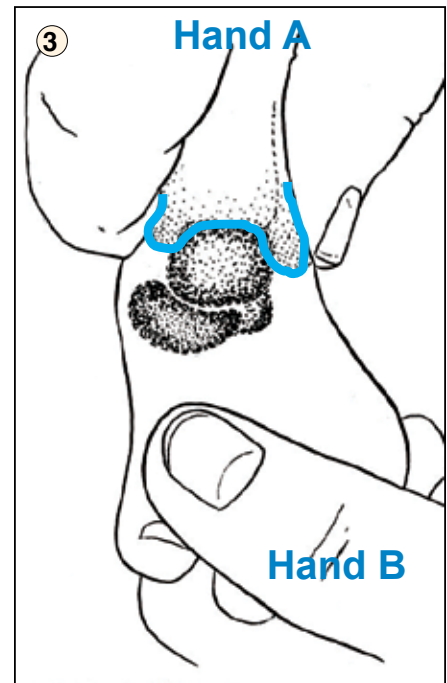
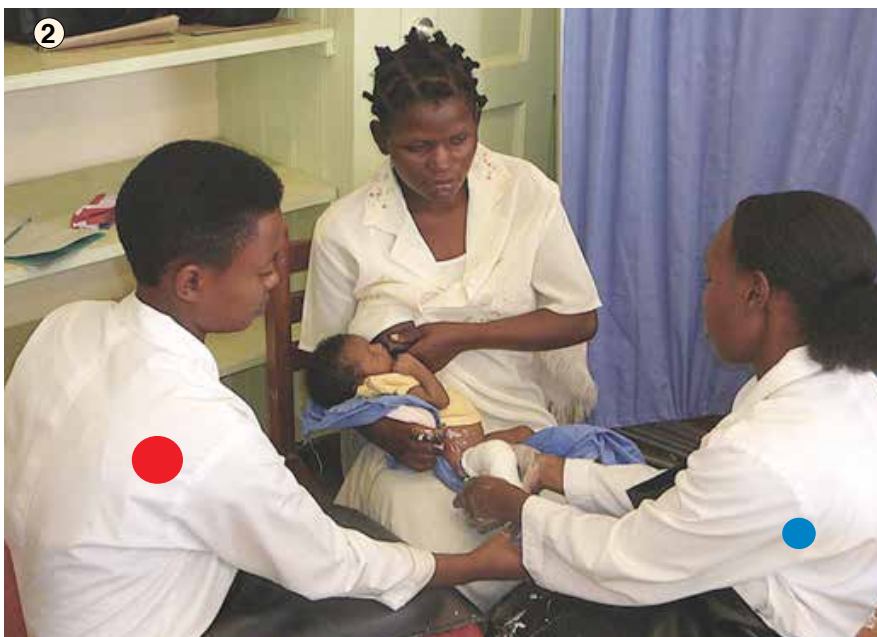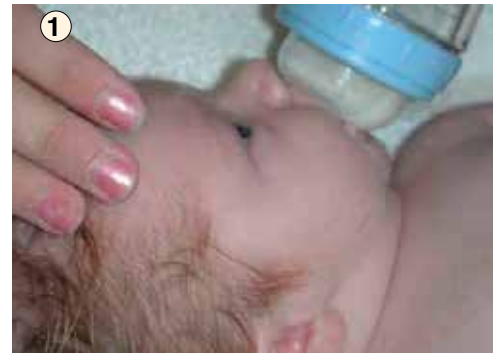Exactly locate the head of the talus

This step is essential [3]. First, palpate the malleoli (blue outline) with the thumb and index finger of hand A while the toes and metatarsals are held with hand B. Next [4], slide your thumb and index finger of hand A forward to palpate the head of the talus (red outline) in front of the ankle. Because the navicular is medially displaced and its tuberosity is almost in contact with the medial malleolus, you can feel the prominent lateral part of the talar head (red) barely covered by the skin in front of the lateral malleolus. The anterior part of the calcaneus will be felt beneath the talar head.

While moving the forefoot laterally in supination, you will be able to feel the navicular move ever so slightly in front of the head of the talus as the calcaneus moves laterally under the talar head.

Manipulation

The manipulation consists of abduction of the foot beneath the stabilized talar head. Locate the head of the talus. All components of clubfoot deformity, except for the ankle equinus, are corrected simultaneously. To gain this correction, you must locate the head of the talus, which is the fulcrum for correction.



Reduce the cavus

The first element of management is correction of the cavus deformity by positioning the forefoot in proper alignment with the hindfoot. The cavus, which is the high medial arch [1 yellow arc] is due to the pronation of the forefoot in relation to the hindfoot. The cavus is always supple in newborns and requires only elevating the first ray of the forefoot to achieve a normal longitudinal arch of the foot [2 and 3]. The forefoot is supinated to the extent that visual inspection of the plantar surface of the foot reveals a normal appearing arch—neither too high nor too flat. Alignment of the forefoot with the hindfoot to produce a normal arch is necessary for effective abduction of the foot to correct the adductus and varus.

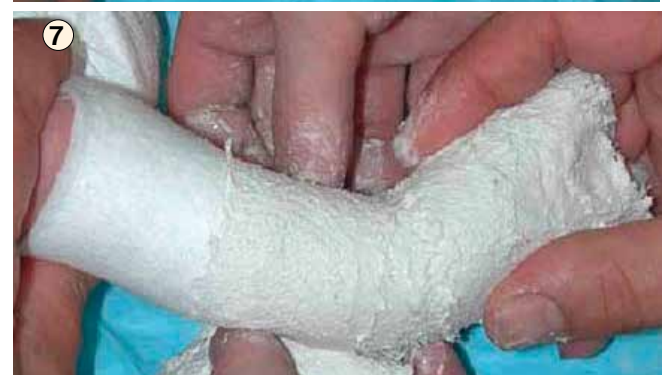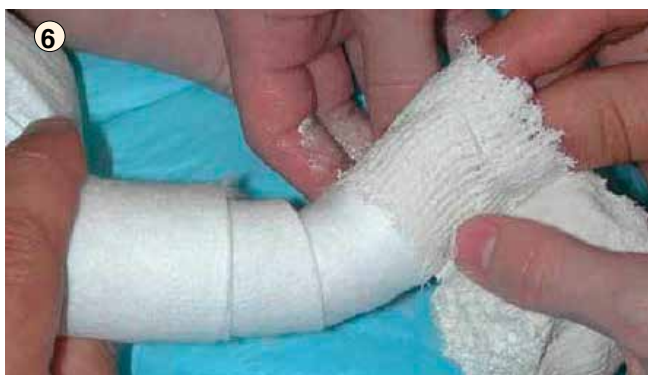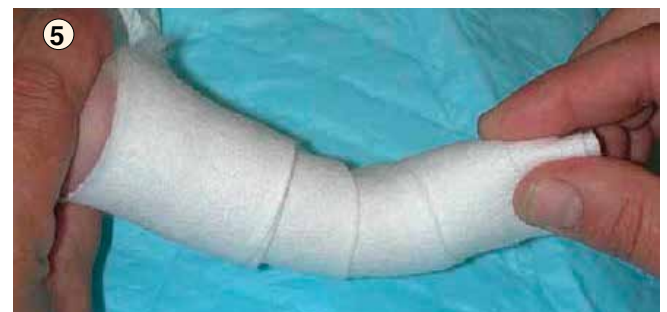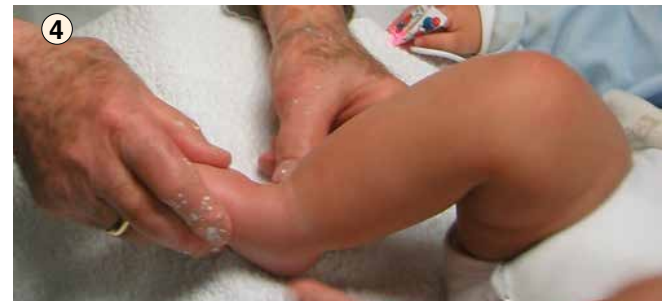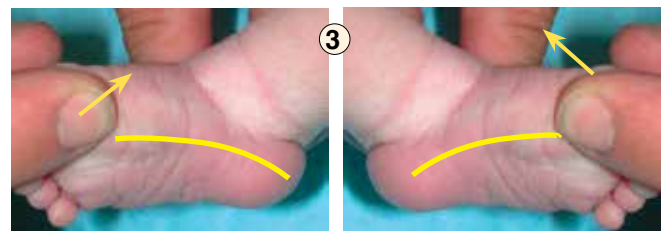
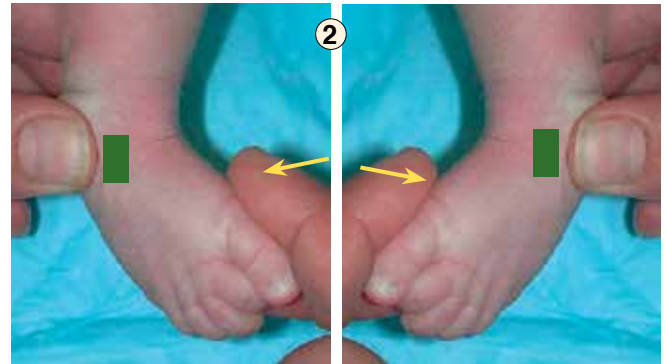
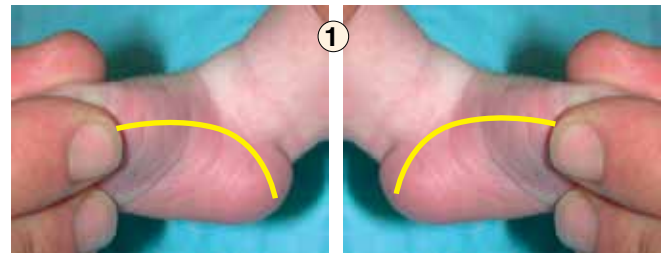
Steps in cast application

Dr. Ponseti recommends the use of plaster material because it is less expensive and more precisely molded than fiberglass.

Preliminary manipulation Before each cast is applied, the foot is manipulated. The heel is not touched to allow the calcaneus to abduct with the foot [4].

Applying the padding Apply only a thin layer of cast padding [5] to allow molding of the foot. Maintain the foot in the maximum corrected position by holding the toes with counter-pressure applied against the head of the talus while the cast is being applied.

Applying the cast First apply the cast below the knee and then extend the cast to the upper thigh. Begin with three to four turns around the toes [6], and then work proximally up to the knee [7]. Apply the plaster smoothly. Add a little tension to the turns of plaster above the heel. The foot should be held by the toes and plaster wrapped over the “holder’s” fingers to provide ample space for the toes.



Molding the cast Do not try to force correction with the plaster. Use light pressure.

Do not apply constant pressure with the thumb over the head of the talus; rather, press and release repetitively to avoid pressure sores of the skin. Mold the plaster over the head of the talus while holding the foot in the corrected position [1]. Note that the thumb of the left hand is molding over the talar head while the right hand is molding the forefoot in supination. The arch is well molded to avoid flatfoot or rocker-bottom deformity. The heel is well molded by countering the plaster above the posterior tuberosity of the calcaneus. The malleoli are well molded. The calcaneus is never touched during the manipulation or casting. Molding should be a dynamic process; constantly move the fingers to avoid excessive pressure over any single site. Continue molding while the plaster hardens.

Extend cast to thigh Use much padding at the proximal thigh to avoid skin irritation [2]. The plaster may be layered back and forth over the anterior knee for strength [3] and for avoiding a large amount of plaster in the popliteal fossa area, which makes cast removal more difficult.

Trim the cast Leave the plantar plaster to support the toes [4], and trim the cast dorsally to the metatarsal phalangeal joints, as marked on the cast. Use a plaster knife to remove the dorsal plaster by cutting the center of the plaster first and then the medial and lateral plaster. Leave the dorsum of all the toes free for full extension. Note the appearance of the first cast when completed [5]. The foot is in equinus, and the forefoot is supinated.

Characteristics of adequate abduction

Confirm that the foot is sufficiently abducted to safely bring the foot into 0 to 5 degrees of dorsiflexion before performing tenotomy.

The best sign of sufficient abduction is the ability to palpate the anterior process of the calcaneus as it abducts out from beneath the talus.

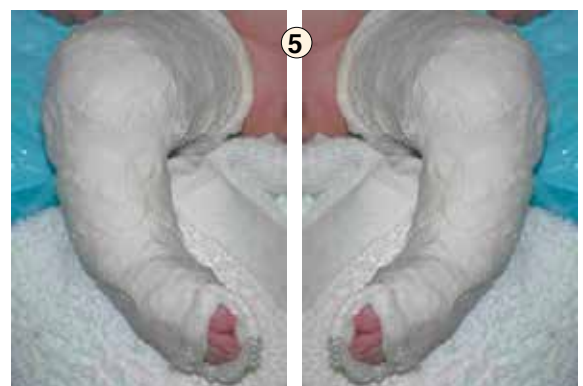
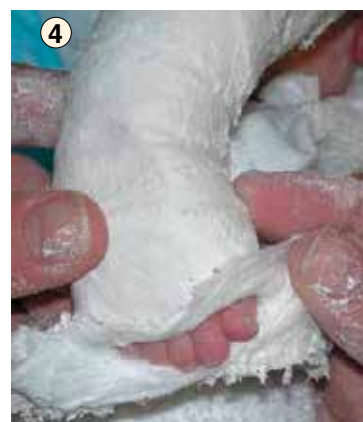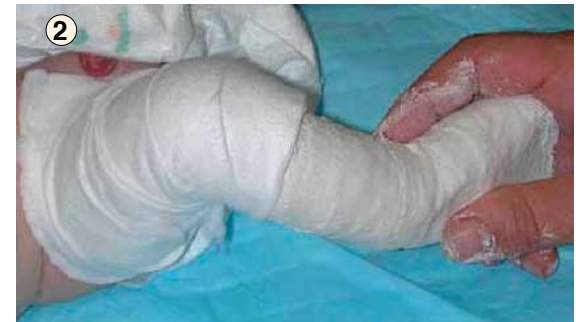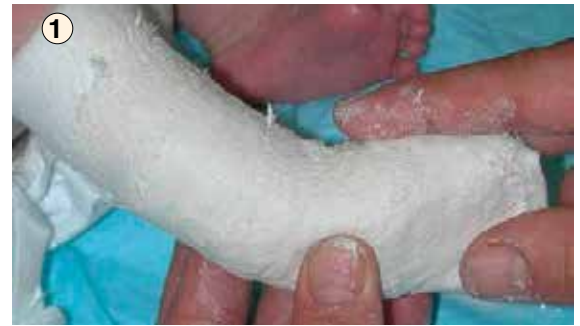Abduction of approximately 60 degrees in relationship to the frontal plane of the tibia is possible.

Neutral or slight valgus of os calcis is present. This is determined by palpating the posterior os calcis.

Remember that this is a three-dimensional deformity and that these deformities are corrected together. The correction is accomplished by abducting the foot under the head of the talus. The foot is never pronated.

The final outcome

At the completion of casting, the foot appears to be over-corrected into abduction with respect to normal foot appearance during walking. This is not in fact an overcorrection. It is actually a full correction of the foot into maximum normal abduction. This correction to complete, normal, and full abduction helps prevent recurrence and does not create an over-corrected or pronated foot.



Complications of Casting

Using careful technique, as described, complications are uncommon.

Rocker-bottom deformity is due to poor technique by dorsiflexing the foot too early against a very tight Achilles tendon.

Crowded toes are due to tight casting over the toes.

Flat heel pad will occur if, while casting, pressure is applied to the heel rather than molding the cast above the ankle.

Superficial sores are managed by applying a dressing and a new cast with additional padding.

Pressure sores are due to poor technique. Common sites include the head of the talus, over the heel, under the first metatarsal head, and popliteal and groin regions.

Deep sores are dressed and left out of the cast for one week to allow healing. Casting is then resumed with special care to avoid relapse.

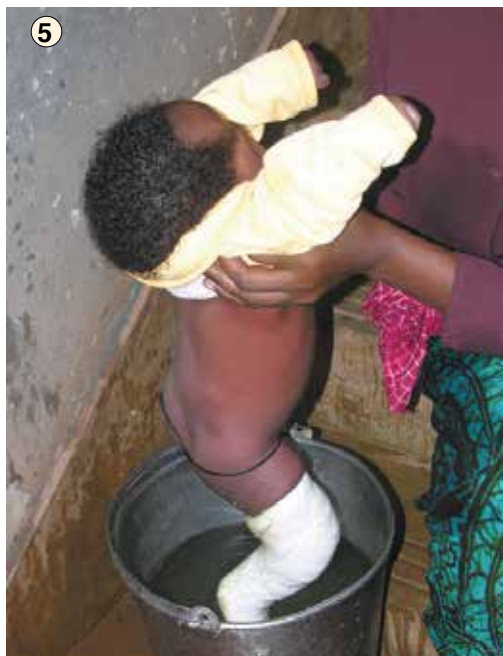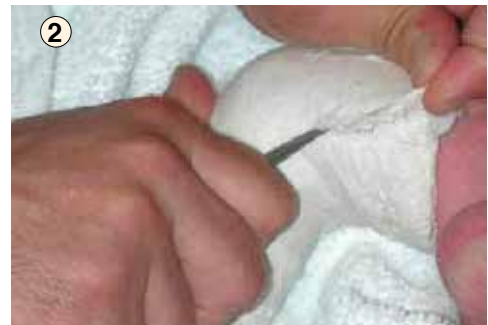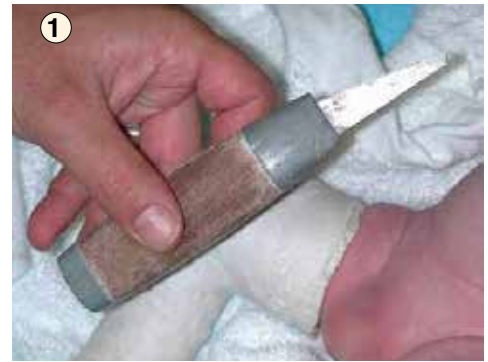Cast removal

Remove each cast in clinic just before a new cast is applied. Avoid cast removal before clinic because considerable correction can be lost from the time the cast is removed until the new one is placed.

Options for removal Avoid using a cast saw because it is frightening to the infant and family and may also cause injury to the skin.

Cast knife removal Soak the cast in water for about 20 minutes, and then wrap the cast in wet cloths before removal. This can be done by the parents at home just before their visit. Use the plaster knife [1], and cut obliquely [2] to avoid cutting the skin. Remove the above-knee portion of the cast first [3]. Finally, remove the below-knee portion of the cast [4].

Soaking and unwrapping This is an effective method, but requires more time. Soak cast thoroughly in water [5] and when completely soft unwrap the plaster [6]. To make this process easier, leave the end of the plaster free for identification.



Common Management Errors

Pronation or eversion of the foot

This position worsens the deformity [1] by increasing the cavus. Pronation does nothing to abduct the adducted and inverted calcaneus, which remains locked under the talus. It also creates a new deformity of eversion through the mid and forefoot, leading to a bean-shaped foot. *“Thou shall not pronate!”*

External rotation of foot to correct adduction while calcaneus remains in varus

This causes a posterior displacement of the lateral malleolus by externally rotating the talus in the ankle mortise. This displacement is an iatrogenic deformity.

Avoid this problem by abducting the foot in flexion and slight supination to stretch the medial tarsal ligaments, with counter-pressure applied on the lateral aspect of the head of the talus [2 thumb position]. This allows the calcaneus to abduct under the talus with correction of the heel varus.

Kite's method of manipulation

Kite believed that the heel varus would correct simply by everting the calcaneus. He did not realize that the calcaneus can evert only when it is abducted (i.e., laterally rotated) under the talus.

Abducting the foot at the midtarsal joints with the thumb pressing on the lateral side of the foot near the calcaneocuboid joint [2 black dot] blocks abduction of the calcaneus and interferes with correction of the heel varus. Make certain the foot is abducted around the head of the talus [2 red dot].

Casting errors

Failure to manipulate The foot should be immobilized with the contracted ligaments at maximum stretch obtained after each manipulation. In the cast, the ligaments loosen, allowing more stretching at the next session.

Short-leg cast The cast must extend to the groin. Short-leg casts do not hold the calcaneus abducted [3].

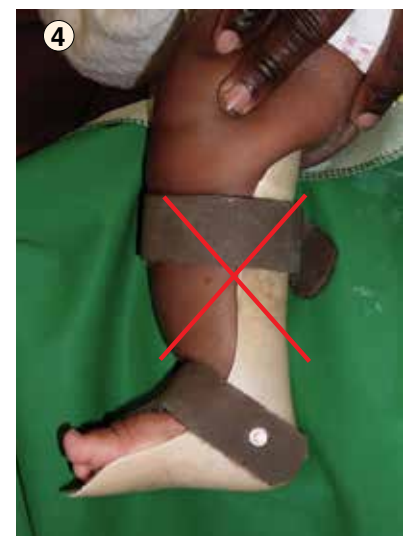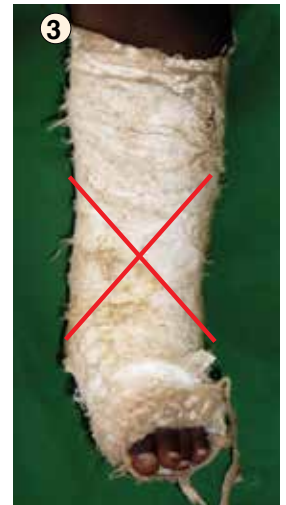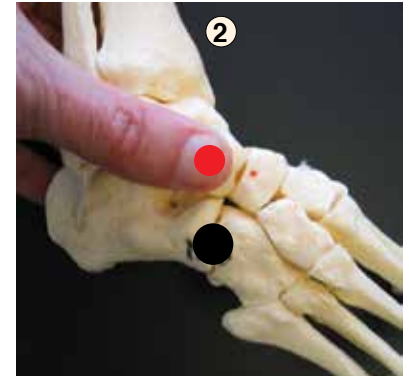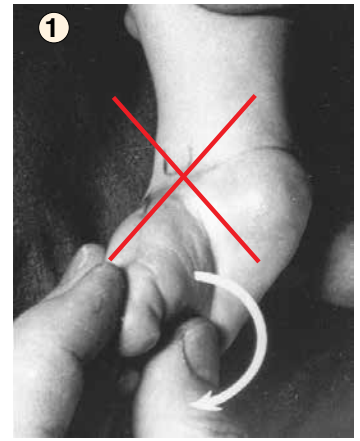Premature equinus correction Attempts to correct the equinus before the heel varus and foot supination are corrected will result in a rocker-bottom deformity. Equinus through the subtalar joint can be corrected by calcaneal abduction.

Failure to use appropriate night bracing

Avoid using a short leg brace [4] as it fails to hold the foot in abduction. The external bar brace should be used full time for 3 months and at night for 4 years. Failure of appropriate bracing is the most common cause of relapse.

Attempts to obtain perfect anatomical correction

It is wrong to assume that early alignment of the displaced skeletal elements will result in normal anatomy. Long-term follow-up radiographs show abnormalities. However, good long-term function of the clubfoot can be expected. There is no correlation between the radiographic appearance of the foot and long-term function.



Tenotomy

Indication for tenotomy

Tenotomy is indicated to correct equinus when cavus, adductus, and varus are fully corrected but ankle dorsiflexion remains less than 10 degrees above neutral. Make certain that abduction is adequate for performing the tenotomy.

Characteristics of adequate abduction

Confirm that the foot is sufficiently abducted to safely bring the foot into 0 to 5 degrees of dorsiflexion before performing tenotomy.

The best sign of sufficient abduction is the ability to palpate the anterior process of the calcaneus as it abducts out from beneath the talus.

Abduction of approximately 60 degrees, in relationship to the frontal plane of the tibia is possible.

Neutral or slight valgus of os calcis is present. This is determined by palpating the posterior os calcis.

Remember that this is a three-dimensional deformity and that these deformities are corrected together. The correction is accomplished by abducting the foot under the head of the talus. The foot is never pronated.

Preparation

Preparing the family Prepare the family by explaining the procedure. Explain that tenotomy is a minor procedure performed under local anesthetic in the outpatient clinic.

Equipment Prepare all of the material in advance [1]. Select a tenotomy blade, such as a #11 or #15, or any other small blade, such as an ophthalmic knife.

Skin preparation Prep the foot thoroughly from midcalf to midfoot with an antiseptic while the assistant holds the foot from the toes with the fingers of one hand and the thigh with the other [1 next page].

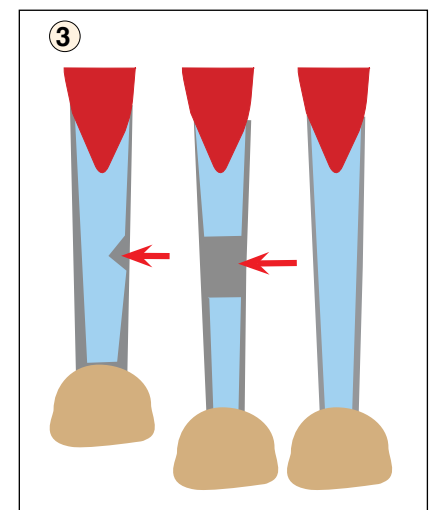
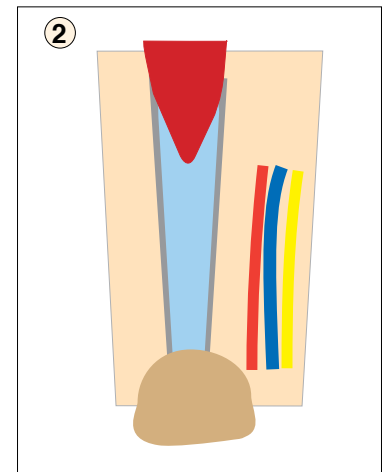
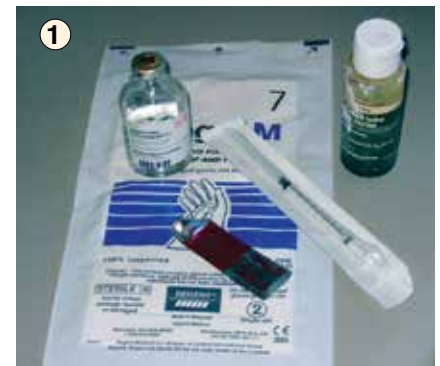Anesthesia A small amount of local anesthetic may be infiltrated near the tendon [2 next page]. Be aware that too much local anesthetic makes palpation of the tendon difficult and the procedure more complicated.

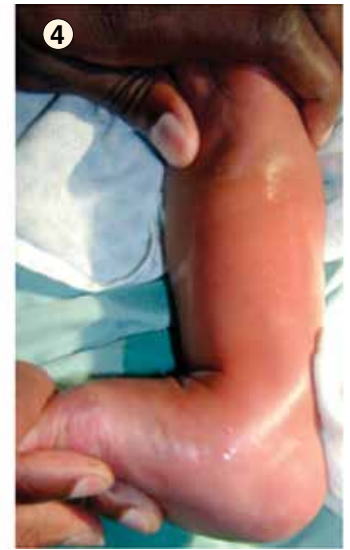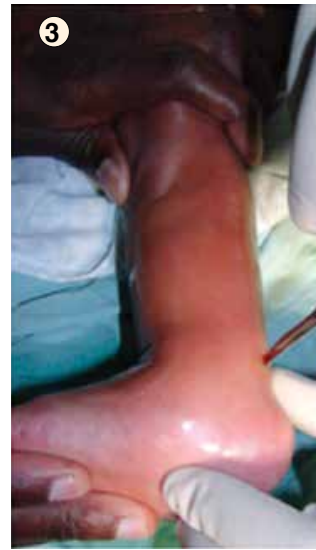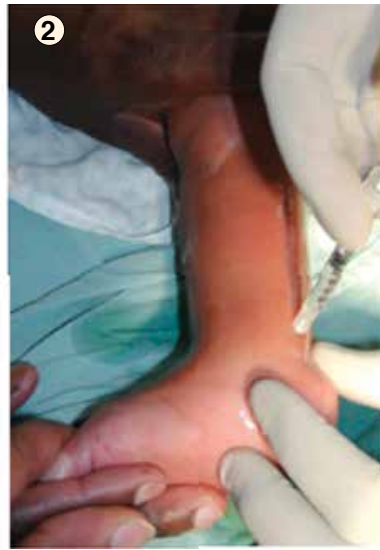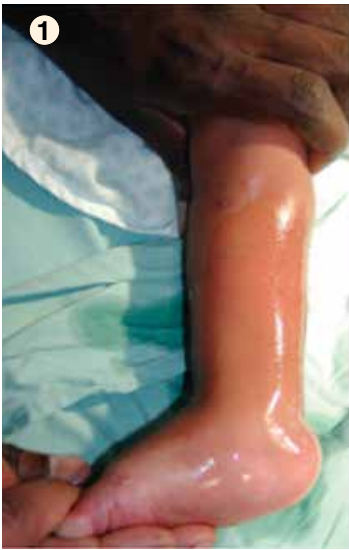Setup for the tenotomy

With the assistant holding the foot in maximum dorsiflexion, select a site about 1.5 cm above the calcaneus for the tenotomy. Infiltrate a small amount of local anesthetic just medial to the tendon at the site selected for the tenotomy. Be aware that too much local anesthetic makes palpation of the tendon difficult and the procedure more complicated. Keep in mind the anatomy. The neurovascular bundle is antero-medial to the heel cord [2]. The heel-cord tendon (light blue) lies within the tendon sheath (grey).

Tenotomy

Insert the tip of the scalpel blade from the medial side, directed immediately anterior to the tendon [3 next page]. Keep the flat part of the blade parallel to the tendon. The initial entry causes a small longitudinal incision. Care must be taken to be gentle so as not to accidentally make a large skin incision. The tendon sheath (grey) is not divided and left intact [3]. The blade is then rotated, so that its sharp edge is directed posteriorly towards the tendon. The blade is then moved a little posteriorly. A “pop” is felt as the sharp edge releases the tendon. The tendon is not cut completely unless a “pop” is appreciated. An additional 15 to 20 degrees of dorsiflexion is typically gained after the tenotomy [4 next page].





Post-tenotomy cast

After correction of equinus by tenotomy, apply the fifth cast [5] with the foot abducted 60 to 70 degrees with respect to the frontal plane of the ankle, and 15 degrees dorsiflexion. The foot looks over-corrected with respect to the thigh. This cast holds the foot for 3 weeks after complete correction. It should be replaced if it softens or becomes soiled before 3 weeks. The baby and mother may go home immediately. Usually no analgesic is necessary. This is usually the last cast required in the treatment program.

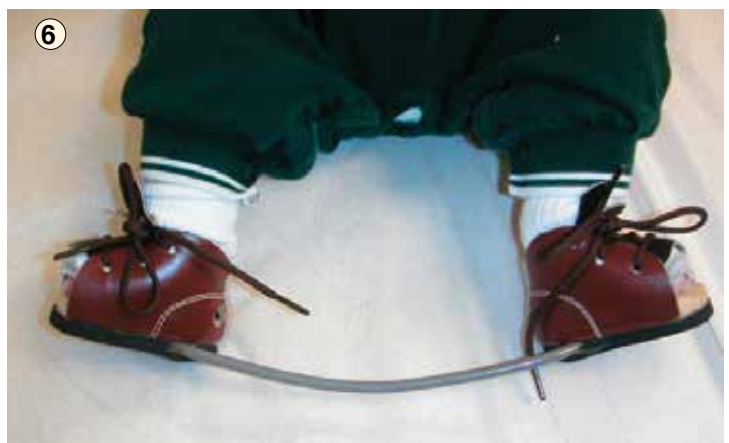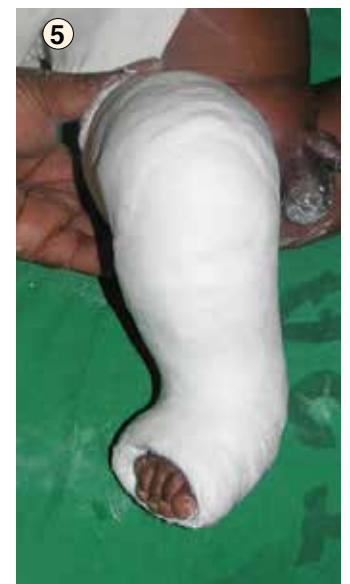Cast removal

After 3 weeks, the cast is removed. Twenty degrees of dorsiflexion is now possible. The tendon is healed. The operative scar is minimal. The foot is ready for bracing [6ww]. The foot appears to be over-corrected into abduction. This is often a concern to the caregiver. Explain that this is not an overcorrection, only full abduction.

Errors during tenotomy

Premature equinus correction Attempts to correct the equinus before the heel varus and foot supination are corrected will result in a rocker-bottom deformity. Equinus through the subtalar joint can be corrected only if the calcaneus abducts. Tenotomy is indicated after cavus, adductus, and varus are fully corrected.

Failure to perform a complete tenotomy The sudden lengthening with a “pop” or “snap” signals a complete tenotomy. Failure to achieve this may indicate an incomplete tenotomy. Repeat the tenotomy maneuver to ensure a complete tenotomy if there is no “pop” or “snap.”



Bracing

Bracing is essential

At the end of casting, the foot is abducted to an exaggerated amount, which should measure 60 to 70 degrees (thigh-foot axis). After the tenotomy, the final cast is left in place for 3 weeks. Ponseti's protocol then calls for a brace to maintain the foot in abduction and dorsiflexion. This is a bar attached to straight-last open-toe shoes. This degree of foot abduction is required to maintain the abduction of the calcaneus and forefoot and prevent relapse. The medial soft tissues remain stretched out only if the brace is used after the casting. In the brace, the knees are left free, so the child can kick them "straight" to stretch the gastrosoleus tendon. The abduction of the feet in the brace, combined with the slight bend (convexity away from the child), causes the feet to dorsiflex. This helps maintain the stretch on the gastrocnemius muscle and heel-cord tendon. Ankle-foot orthoses (AFO's) are not useful because they only keep the foot straight with neutral dorsiflexion.

Bracing protocol

Three weeks after the tenotomy, the cast is removed and a brace is applied immediately. The brace consists of open-toe high-top straight-last shoes attached to a bar [1]. For unilateral cases, the brace is set at 60 to 70 degrees of external rotation on the clubfoot side and 30 to 40 degrees of external rotation on the normal side [2]. In bilateral cases, it is set at 70 degrees of external rotation on each side. The bar should be of sufficient length so that the heels of the shoes are at shoulder width [2]. A common error is to prescribe too short a bar, that the child finds uncomfortable. A narrow brace is a common reason for a lack of compliance. The bar should be bent 5 to 10 degrees with the convexity away from the child, to hold the feet in dorsiflexion.

The brace should be worn full time (day and night) for the first 3 months after the last cast is removed. After that, the child should wear the brace for 12 hours at night and 2 to 4 hours in the middle of the day, for a total of 14 to 16 hours during each 24-hour period. This protocol continues until the child is 3 to 4 years of age.

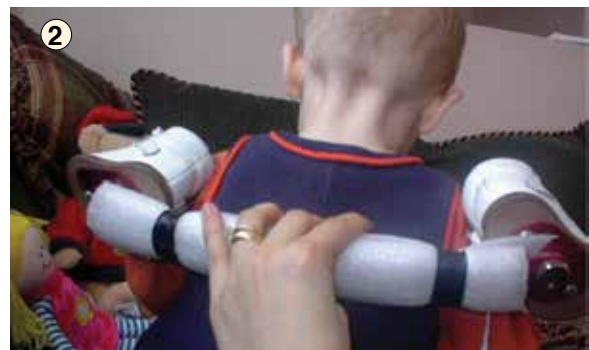
Occasionally, a child will develop excessive heel valgus and external tibial torsion while using the brace. In such instances, the physician should reduce the external rotation of the shoes on the bar from approximately 70 degrees to 40 degrees.

Importance of bracing

The Ponseti manipulations combined with the percutaneous tenotomy regularly achieve an excellent result. However, without a diligent follow-up bracing program, relapse occurs in more than 80% of cases. This is in contrast to a relapse rate of only 6% in compliant families (Morcuende et al.).

When to stop bracing

How long should the nighttime bracing protocol continue? As it is often difficult to determine severity, we recommend that all feet should be braced for to 3 to 4 years. Most children get used to the bracing, and it becomes part of their lifestyle. If after 3 years of age compliance becomes a problem, it may become necessary to discontinue the bracing. The child is closely followed for evidence of relapse. Should early relapse be observed, bracing should be promptly started again.



Types of braces

Modifications of the original Ponseti brace provide some advantages. To prevent the foot from sliding out of the shoe, a pad may be placed in the counter of the shoe [1]. New designs make the foot more secure in the brace, more easily applied to the infant, and allow the infant to move. This flexibility may improve compliance. Several of the brace options are shown [1–7].

H.M. Steenbeek working for the Christoffel Blinden Mission in Katalamwa Cheshire Home in Kampala, Uganda, developed a brace that can be made from simple, easily available materials [2]. The brace is effective in maintaining correction, easy to use, easy to fabricate, inexpensive, and ideally suited for widespread use (see page 26). For construction details contact Michiel Steenbeek at steenbeek.michiel@gmail.com or global-help.org.


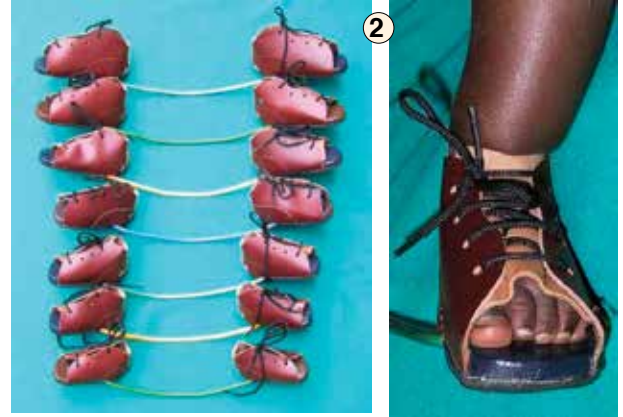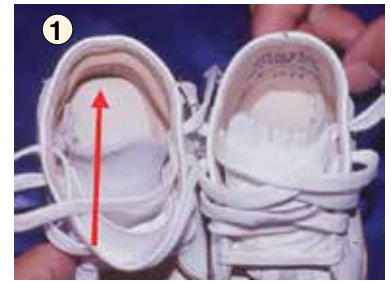
John Mitchell has designed a brace under Dr. Ponseti's direction. This brace consists of shoes made of a very soft leather and a plastic sole that is molded to the shape of the child's foot, making this shoe very comfortable and easy to use [3]. See: www.mdorthopaedics.com.

Dr. Matthew Dobbs of the Washington University School of Medicine in St. Louis, USA developed a new dynamic brace for clubfoot that allows the foot to move while maintaining the required rotation of the foot [4]. An ankle-foot orthoses are required as part of this brace to prevent ankle plantar flexion.

M.J. Markel developed a brace that allows the parent to first place the shoes on the infant and then "click" each shoe onto the bar [5].

Dr. Jeffrey Kessler of the Kaiser Hospital in Los Angeles, USA developed a brace that is flexible and inexpensive. The bar is made of 1/8" thick polypropylene [6]. The brace may improve compliance because it is well accepted by the infant. See JPO-B 17:247 2008.

Dr. Romanus developed this brace in Sweden [7]. The shoes are made of malleable plastic that is molded to the shape of the child's foot. The inside is covered by very smooth leather, which makes the construct very comfortable. The shoes are fixed to the bar with screws.



Increasing Brace Compliance

The most compliant families are those who understand Ponseti management and the importance of bracing.

Continued education

Take every opportunity to educate the family about Ponseti management.

Written material is very helpful when available. Often published material is more convincing than information given verbally [1].

During weekly casting While applying each cast, take the opportunity to discuss management and emphasize the importance of the bracing that maintains correction. Answer questions from the parents or other family members. Focus attention on family members who may appear skeptical, and then address their concerns.

Prepare family for bracing Anticipate that failures are most likely due to premature discontinuation of bracing. Repeatedly emphasize the importance of this phase of management. Make families aware that maintaining the correction with bracing is equally important to gaining the correction by casting and tenotomy.

Instructions for bracing

Assigning responsibility Once correction has been achieved, clearly pass the responsibility to the family to maintain the correction with bracing. Assigning that responsibility to the father may be appropriate in some situations.

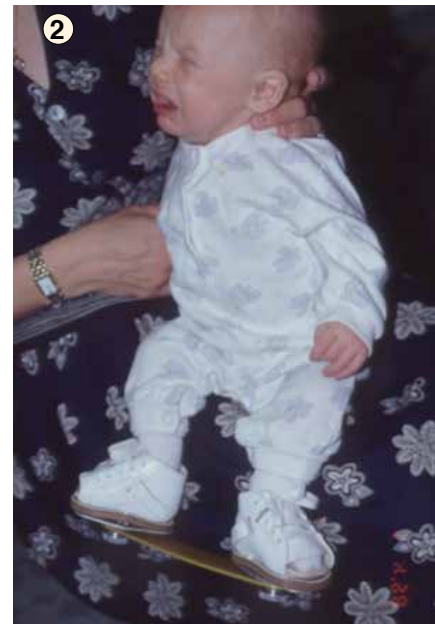Demonstrate families' ability to apply the brace Demonstrate how to apply the brace. Remove the brace and ask the parent to apply the brace while being supervised. Make certain the infant is comfortable in the brace. If the infant is uncomfortable, remove the brace and examine the skin for evidence of irritation with reddening of the skin [2].

Preparing the infant For the first few days, suggest that the brace may be removed for brief periods to improve tolerance. Advise the parents to avoid removing the brace if the infant cries. If the infant learns that by crying the brace will be removed, the pattern will be difficult to correct. Encourage the family to make the bracing a part of the normal life of the infant [3].

Follow-up

Schedule a return visit in 10–14 days to monitor the use of the brace. If the bracing is going well, schedule the next visit in about 3 months. At that time, the bracing may be discontinued during the day. The brace must be applied for naps during the day and sleep during the night.

Offer help Should the family experience difficulty with bracing, encourage the family to call or to return to clinic.



Cultural Barriers to Ponseti Management

Types of barriers

Other forms of clubfoot management Parents may seek nonPonseti management methods. Traditional medicine and other methods are ineffective, and delays make Ponseti management more difficult. Manage this problem with education of the family, other healthcare providers and the public.

Beliefs In some cultures, communities believe that clubfoot is caused by evil spirits, witchcraft, a curse, or the mother's misdeeds [1]. The beliefs may include misinformation that suggests that Ponseti management is ineffective.

Stigma If it is believed that the clubfoot or other disabilities are due to sins or misdeeds of the family, the child with a disability is a source of shame and is hidden by the family.

Village birth Infants born in villages pose a special problem. They will not normally have the benefit of an examination of the newborn by a trained healthcare worker. The families may have no awareness of the diagnosis or the need for early treatment.

Overcoming barriers

Help parents overcome barriers by the following measures:

Establish clubfoot clinics Make Ponseti management facilities available for everyone in the country.

Involve fathers Encourage fathers to attend the clubfoot clinic with the mothers and to become involved in treatment. Fathers who feel involved and understand are more likely to support the mothers in following treatment for the child [2].

Discuss management and plan follow-up Inform caregivers of the entire treatment plan (20 visits over 4 years). Discussing and planning the entire treatment at the start encourages families to plan how to gather necessary funds. Inform parents if the cost of care will be covered by the hospital. Direct families to Ponseti treatment centers for management.

Partnerships Encourage "care-sharing" partnerships to manage barriers. Parents and other caregivers share the financial burden and other family responsibilities. Healthcare workers share health delivery responsibilities. Consider asking local churches, mosques, service clubs, and relief agencies to assist the very poor by facilitating transport or offering other services.

Education, respect, and reassurance

Educate parents and the community by informing about clubfeet, its causes, and that the medical system can manage these problems. This will help make the condition more acceptable.

Respect mothers' needs to return quickly to their other duties at home by avoiding excessive waiting in clinics.

Reassure that the cause is not the parents' fault and treatment is highly effective but takes time.



Relapses

Recognizing relapses

Once the cast is removed and the bracing is started, plan to see the child back at the following schedule to check for compliance and for evidence of relapse:

At 2 weeks to check for compliance of full-time bracing.

At 3 months to graduate to the nights-and-naps schedule.

Until age 3 check every 4 months to monitor compliance and for relapses.

Age 3 to 4 years check every 6 months.

From 4 years until maturity check every 1 to 2 years.

Early relapses

The infant shows loss of foot abduction and/or of dorsiflexion correction with recurrence of adductus and cavus.

Relapses in toddlers

Check for evidence of deformity both by examining the foot with the infant on the mother's lap, and while walking. As the child walks toward the examiner, look for supination of the forefoot. Supination is due to the tibialis anterior muscle overpowering the weaker peroneals [1]. As the child walks away from the examiner, look for heel varus [2].

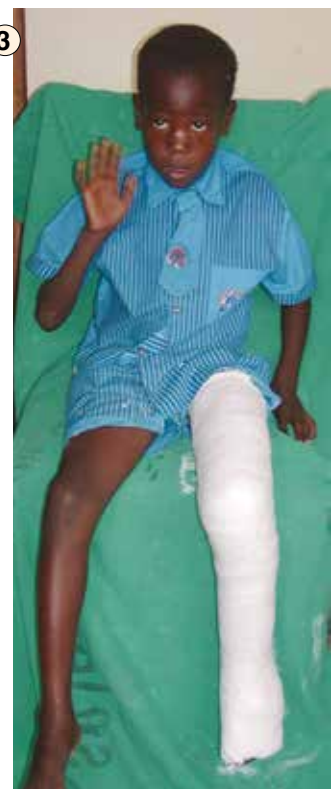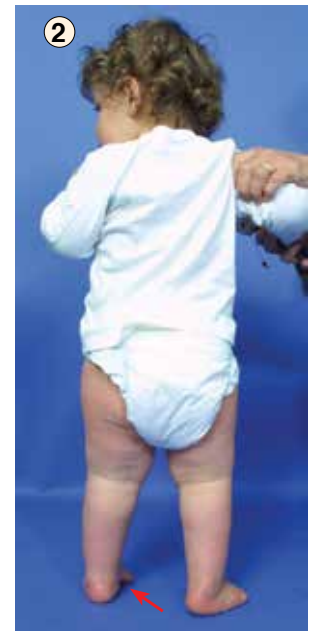The seated child should be examined for ankle range of motion and loss of passive dorsiflexion. Check the range of motion of the subtalar and midtarsal joints. These joints should move freely. A loss of free mobility is evidence of relapse.

Reasons for relapses

The most common cause of relapse is noncompliance of the bracing program. Morcuende found that relapses occur in only 6% of compliant families and in more than 80% of noncompliant families. If relapse occurs in infants who are braced, the cause is an underlying muscle imbalance of the foot that can lead to stiffness and relapse.

Casting for relapses

Do not ignore relapses! At the first sign of relapse, apply one to three casts to stretch the foot out and regain correction. This cast management is the same as the original Ponseti casting program. Once the deformity is corrected by casting, start the bracing program again. Even in the child with a severe recurrence, sometimes casting is very effective [3].



Equinus relapse

Recurrent equinus is a deformity that can complicate management. The tibia seems to grow faster than the gastrosoleus tendon unit. The muscle is atrophic and the tendon appears long and fibrotic [1].

Correct by applying serial long-leg casts with the foot abducted and the knee flexed. Continue weekly casting until the foot can be brought to about 10° of dorsiflexion. If this is not achieved in 4–5 casts in children under 4 years of age repeat the percutaneous heel-cord tenotomy. Once the equinus is corrected, resume the nighttime bracing program.

Varus relapse

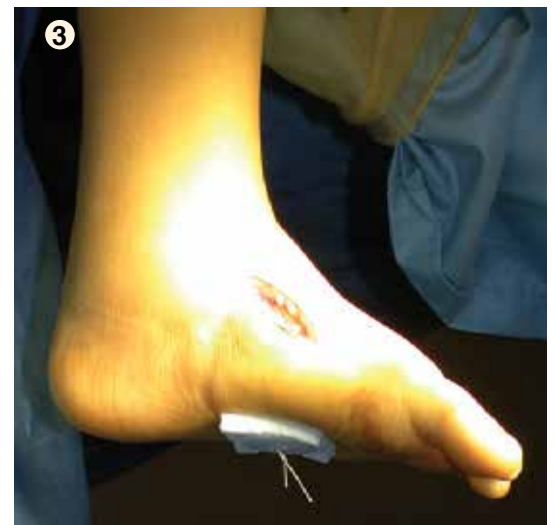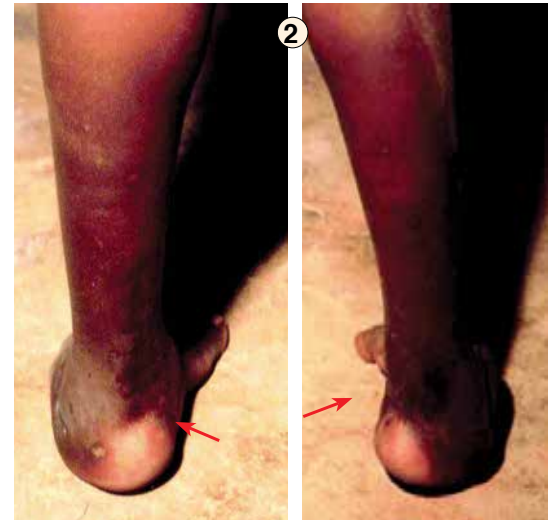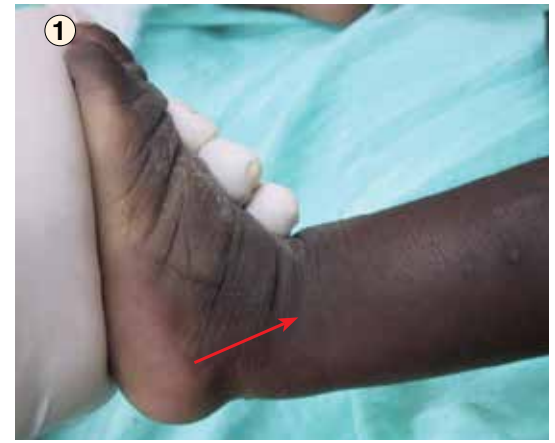Varus heel relapses are more common than equinus relapses. They can be seen with the child standing [2] and should be treated by re-casting in the child between age 12 and 24 months, followed by resuming of a strict bracing program.

Dynamic supination

Some children, usually between ages 3 and 4 years, with only a dynamic supination deformity will benefit from an anterior tibialis tendon transfer [3]. This transfer is only effective if the deformity is dynamic and not fixed. Delay the procedure until after 30 months of age when the lateral cuneiform becomes ossified. Normally, bracing is not required after the transfer.

Conclusion

Relapses that occur after Ponseti management are much easier to deal with than relapses that occur after traditional posteromedial release surgery.



Atypical Clubfoot

Most typical clubfoot correct with about five well-applied Ponseti casts. Some clubfoot have unique features that prolong treatment making management more difficult. These difficult clubfoot may be classified into several categories.

Untreated typical clubfoot

If treatment is delayed, the idiopathic clubfoot management becomes progressively more difficult and prolonged. Full correction is still possible into late childhood.

For example, this 3-year-old boy with untreated clubfoot [1] was managed with six casts [2] followed by a tenotomy and a holding cast for 6 weeks. The foot was fully corrected [3] – courtesy Dr. Shafique Pirani.

Regardless of age, start with standard Ponseti management, recognizing that additional treatment may be required. If correction is incomplete and residual deformity is unacceptable, soft tissue or bony surgery may be required to complete the correction.

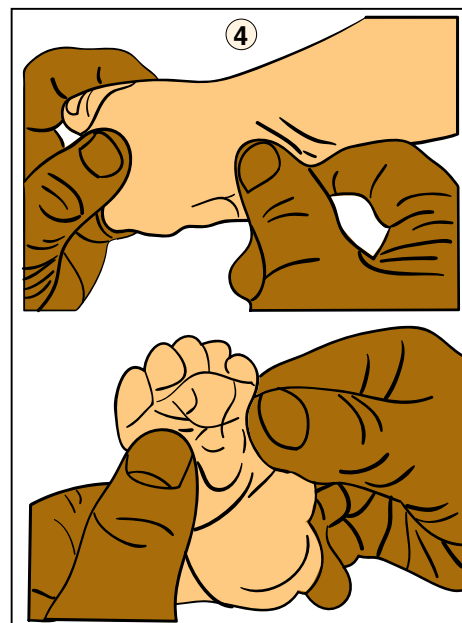
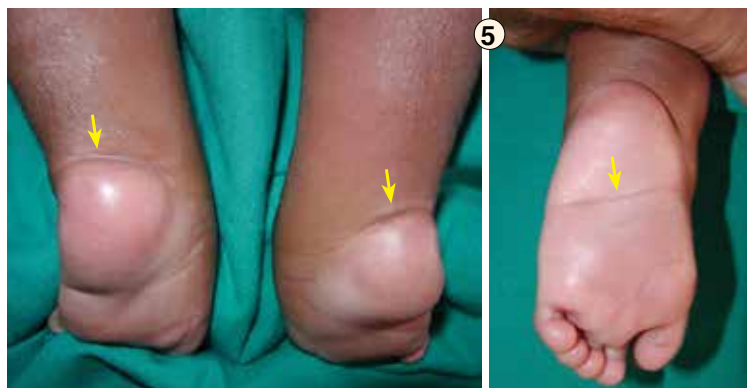
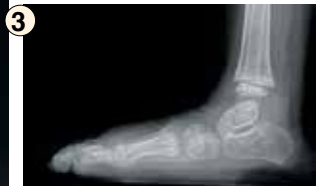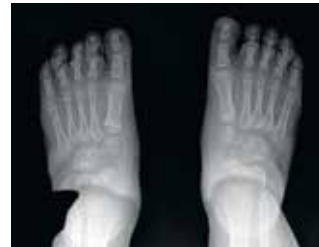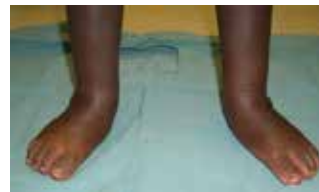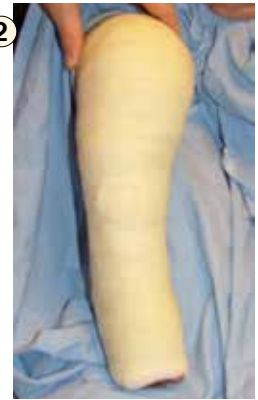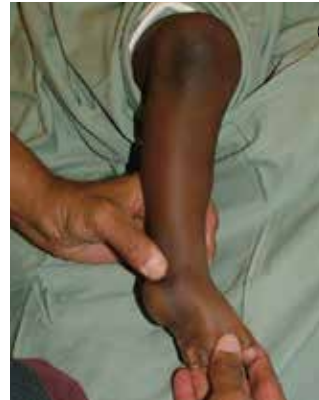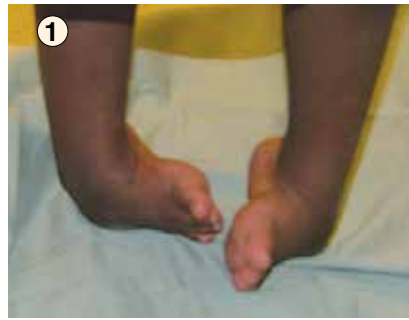Atypical clubfoot

Some clubfoot are more difficult to correct. These resistant clubfeet may be a variant that is unusually stiff. In others, the clubfoot are complex because they were treated by non-Ponseti methods. Such treatment often creates additional deformity that makes management more difficult.

Evaluation Examination often demonstrates severe plantarflexion of all metatarsals, a deep crease just above the heel and across the sole of the midfoot [5 yellow arrows], and a short hyperextended big toe.

Treatment by Ponseti method Start with manipulation and casting. Be aware that treatment will be prolonged and the risk of relapse is increased.

Manipulation Carefully identify the talar head laterally. It is not as prominent as the anterior process of the calcaneus. When manipulating, the index finger should rest over the posterior aspect of the lateral malleolus while the thumb of the same hand applies counterpressure over the lateral aspect of the talar head [4 upper]. Do not abduct more than 30 degrees. After 30 degrees abduction is achieved, change emphasis to correction of the cavus and equinus. All metatarsals are extended simultaneously with both thumbs [4 lower].



Casting Always apply casts with the above-knee portion in 110 degrees flexion to prevent slippage. Up to 6–8 casts can be needed to correct deformity.

Tenotomy A tenotomy is necessary in most cases. Perform the tenotomy when equinus is not corrected. At least 10 degrees dorsiflexion is necessary. Sometimes it is necessary to change casts at weekly intervals after the tenotomy to gain more dorsiflexion, if sufficient dorsiflexion is not achieved immediately after the tenotomy.

Bracing Reduce abduction on the affected side to 30 degrees in the foot abduction brace. The follow-up management remains the same.

Other atypical clubfoot

Clubfoot often coexists with other congenital abnormalities, such as arthrogryposis [1], myelomeningocele [4], and other syndromes. Often the syndrome causes abnormal collagen, creating stiff ligaments, capsules, and other soft tissues. Syndromic clubfoot are more difficult to treat and sometimes require surgery.

Arthrogryposis Start with standard Ponseti casting. Nine to 15 casts are often required. If correction is not achieved, surgery may be required. The magnitude of the surgery will be less as a result of the Ponseti casting. Less extensive procedures such as percutaneous releases of the tendons of the posterior tibialis, heelcord [2] and the great toe flexor [3] may suffice. The postcorrection bracing is essential and may require continuing until mid childhood or longer.

Myelodysplasia Because of sensory loss, casting requires great care to prevent skin ulceration. Apply more padding [5] and avoid excessive pressure in molding.

Other syndromes Clubfoot is often seen in many other syndromes such as dystrophic dysplasia, Möbius syndrome, Larsen syndrome, Wiedemann-Beckwith syndrome, and Pierre Robin syndrome. The long-term functional outcome usually depends more on the underlying syndrome than the clubfoot.

Management of residual deformity

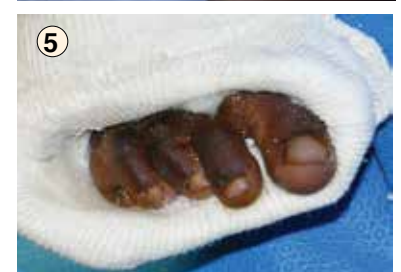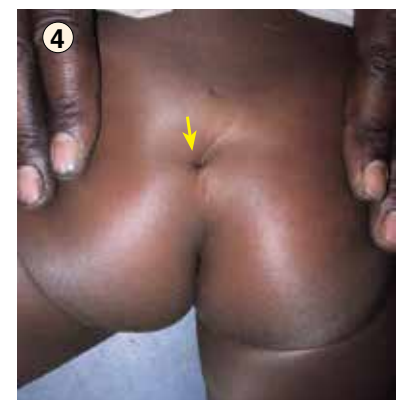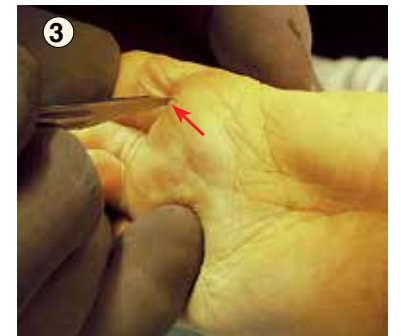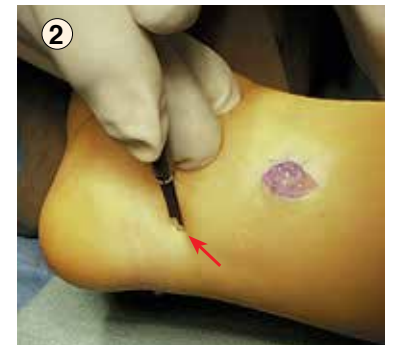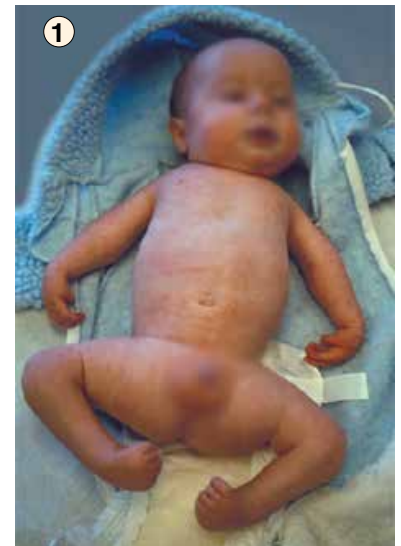If cast correction is incomplete and residual deformity unacceptable, operative correction may be required. Start with Ponseti casting. Even if cast correction is incomplete, the severity of the deformity is reduced and less surgery will be required to complete the correction. Less surgery means less stiffness, weakness, and pain in adult life.

Select the procedure based on the age of the child and severity and type of deformity. Be aware that clubfoot requiring operative correction are prone to recur throughout childhood (25–50%).

Soft tissue release is indicated in infancy and early childhood. The procedure depends upon the severity and location of the deformity.

Bony procedures are indicated and may be used in later childhood. The options include resection and fusions.

Ilizarov frame correction is becoming more commonly performed for older children. Correction is achieved by gradual distraction and repositioning. Reduce the risk of recurrence by over-distraction before correction.



Anterior Tibialis Tendon Transfer

Indication

Transfer is indicated if the child is more than 30 months of age and has a second relapse. Indications include persistent heel varus and forefoot supination during walking; the sole shows thickening of the lateral plantar skin.

Correct deformity

Make certain that any fixed deformity is corrected by two or three casts before performing the transfer. Usually cavus, adductus, and varus correct. Equinus may be resistant. If the foot easily dorsiflexes to 10 degrees, only the transfer is needed. Otherwise a tenotomy of the heelcord is needed.

Anesthesia, positioning and incisions

Put the patient under a general anesthetic, positioned supine. Use a high-thigh tourniquet. Make a dorsolateral incision centered on the lateral cuneiform. Its surface marking is a proximal projection of third metatarsal in front of the head of the talus [1]. The dorso-medial incision is made over the insertion of the anterior tibialis tendon [2].

Expose anterior tibialis tendon

Expose the tendon and detach at its insertion [3]. Avoid extending the dissection too far distally to avoid injury to the growth plate of the first metatarsal.

Place anchoring sutures

Place a #0 dissolving anchoring suture [4]. Make multiple passes through the tendon to obtain secure fixation.

Transfer the tendon

Transfer the tendon subcutaneously to the dorsolateral incision [5]. The tendon remains under the retinaculum and the extensor tendons. Free the subcutaneous tissue to allow the tendon a direct course laterally.

Localize lateral cuneiform

If available, use X-ray. [6]. Note the position of the hole in the radiograph [6 inset arrow]. Otherwise identify by delineating the joint between it and the third metatarsal.

Identify site for transfer

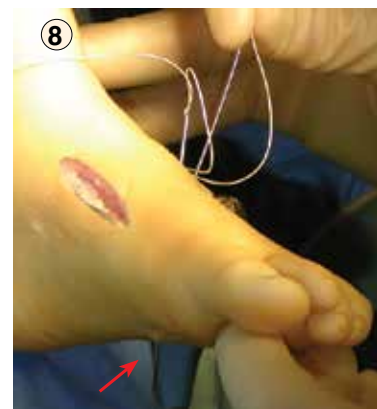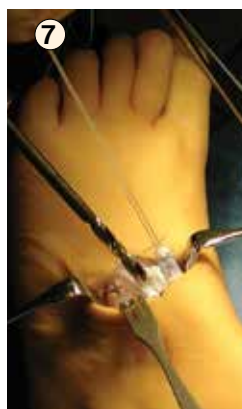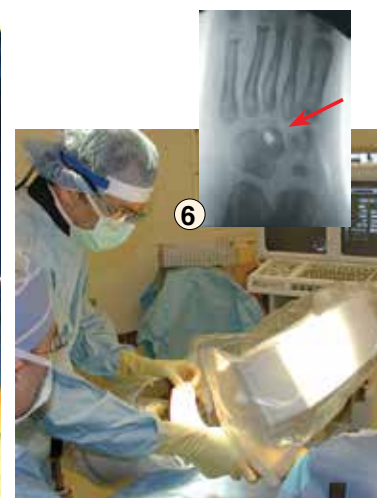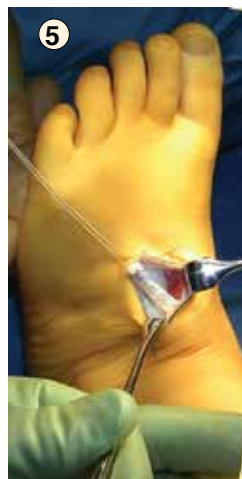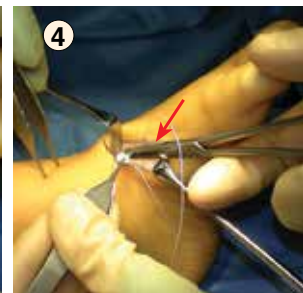
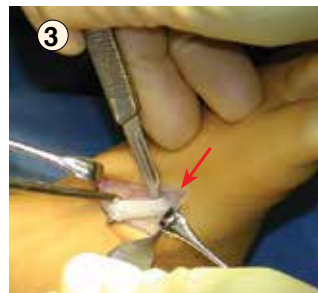
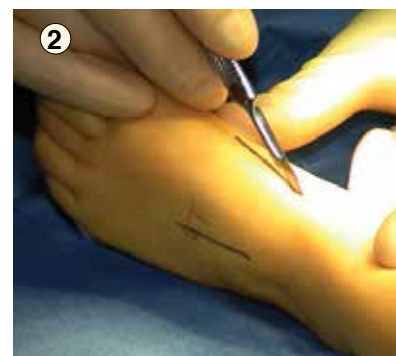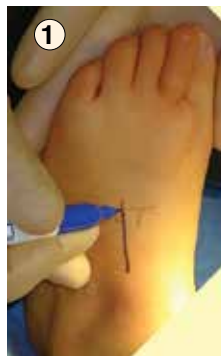Make a drill hole (3.8–4.2) in the middle of the lateral cuneiform large enough to accommodate the tendon [7].

Thread sutures

Thread a straight needle on each of the securing sutures. Pass one needle into the hole. Leave the first needle in the hole while passing the second needle to avoid piercing the first suture [8]. Note that the needle penetrates the sole of the foot [8 arrow].

Consider performing a heel-cord tenotomy

If required, perform a percutaneous tenotomy with a #11 or #15 blade.



Pass two needles

Place the needles through a felt pad and then through different holes in the button to secure the tendon [1].

Secure tendon

With the foot held in dorsiflexion, pull the tendon into the drill hole [2 arrow] by traction on the fixation sutures and tie the fixation suture with multiple knots.

Supplemental fixation

Supplement the button fixation by suturing the tendon to the periosteum at the site where the tendon enters the cuneiform, using a heavy absorbable suture [3].

Local anesthetic

Inject a long-acting local anesthetic into the wound [4] to reduce immediate postoperative pain.

Neutral position without support

Without support, the foot should rest in neutral plantar flexion [5] and neutral valgus-varus.

Skin closure

Close the incisions with absorbable subcutaneous sutures [6]. Tape strips reinforce the closure.

Cast immobilization

Place a sterile dressing and apply a long-leg cast [7]. Keep the foot abducted and dorsiflexed.

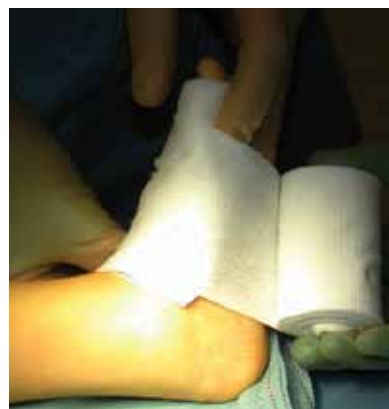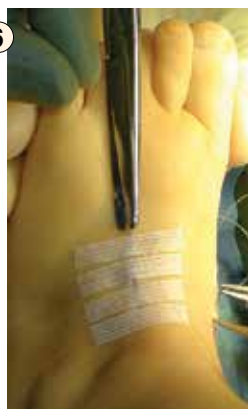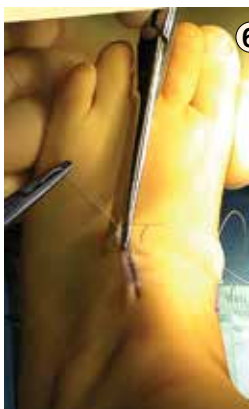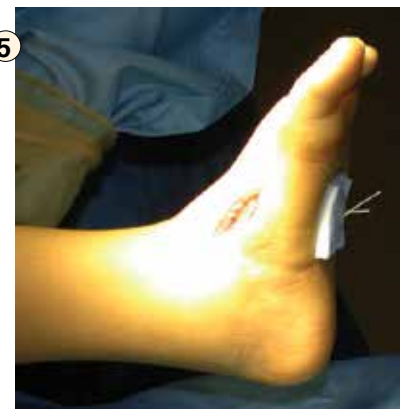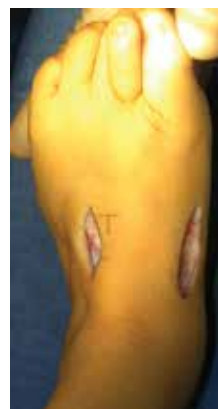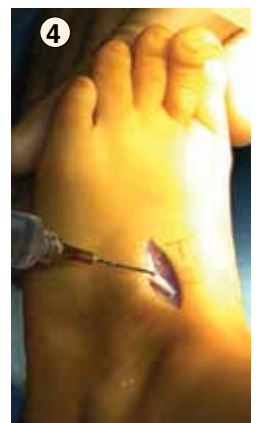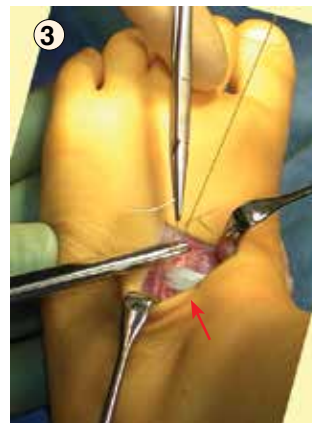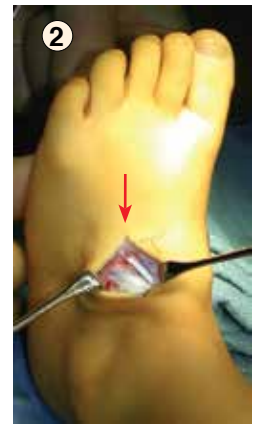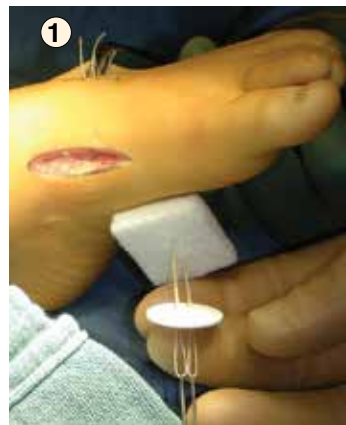Postoperative care

Usually, the patient remains hospitalized overnight. The sutures absorb. Remove the cast and button at 6 weeks. The child may mobilize weight-bearing as tolerated.

Bracing and follow-up

No bracing is necessary after the procedure. See the child again in 6 months to assess the effect of the transfer. In some cases, physical therapy is required to regain strength and normalize gait.

Surgeon: Dr. Vincent Mosca



Brace Manufacture

The success of Ponseti management depends upon an effective brace that is locally available and affordable. Without bracing the clubfoot deformity recurs and treatment fails.

Ideally, braces should be made in the country where treatment is given. This makes the braces more affordable and provides the facility and expertise to mend broken braces.

An ideal example of an effective program is seen in Uganda. Michiel Steenbeek [1] has developed a brace that is made in Uganda and is available throughout the region [3]. This brace is made with widely available materials [2] and tools that are commonly available.

Materials and tools

Brace manufacture requires only leather, lining, plywood, and mild steel rod stock. Fabrication requires tools for making shoes. Required equipment includes a leather-sewing machine [4], metal-working equipment and welding tools.

Cost

The cost of the brace in Uganda is less than US \$10.

Training

To create a sustainable program, train local individuals to make the braces. Orthotic students who have learned the technique will become ideal partners for the future.

The Steenbeek brace production manual

This manual is available with full color illustrations and patterns for all brace sizes, on the web at:
www.global-help.org
or email:
steenbeek.michiel@gmail.com.



Clubfoot Scoring

The need for clubfoot scoring is controversial. Proponents find serial scoring useful in classifying the clubfoot, assessing progress, showing signs of recurrence, and establishing the prognosis. There are two commonly used methods of scoring.

Pirani Score

The Pirani Clubfoot Score documents the severity of the deformity and sequential scores are an excellent way to monitor progress.

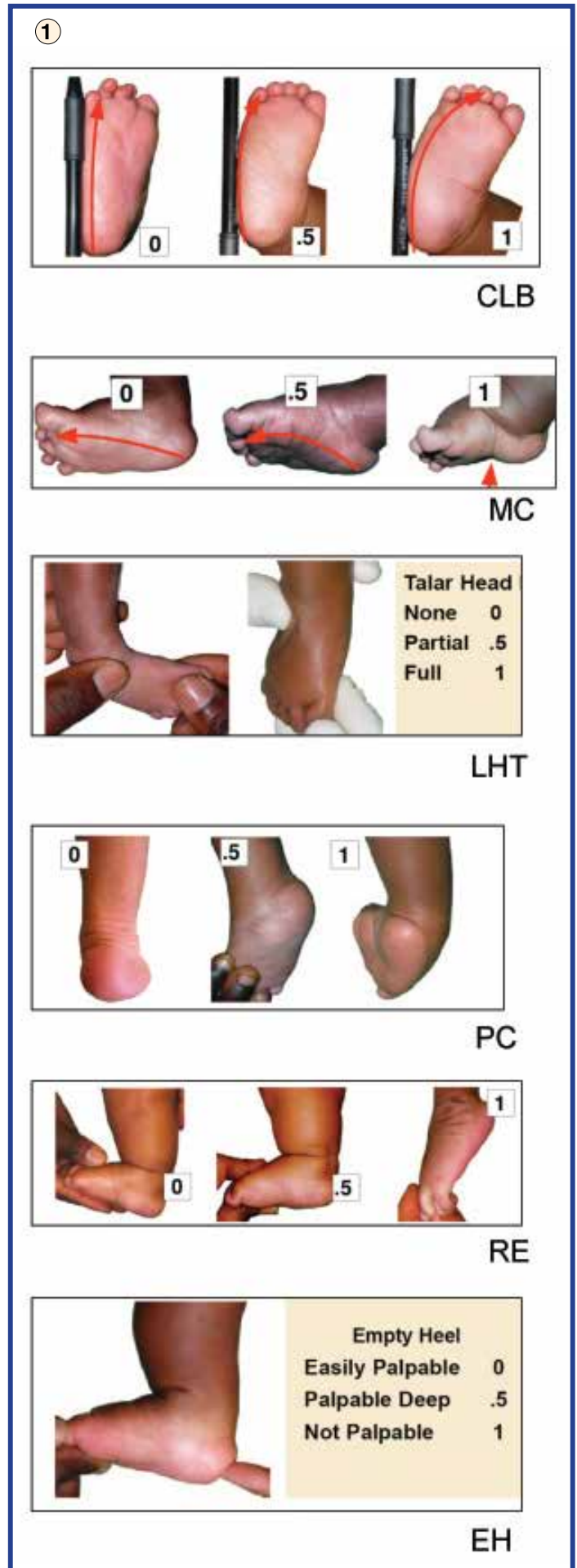
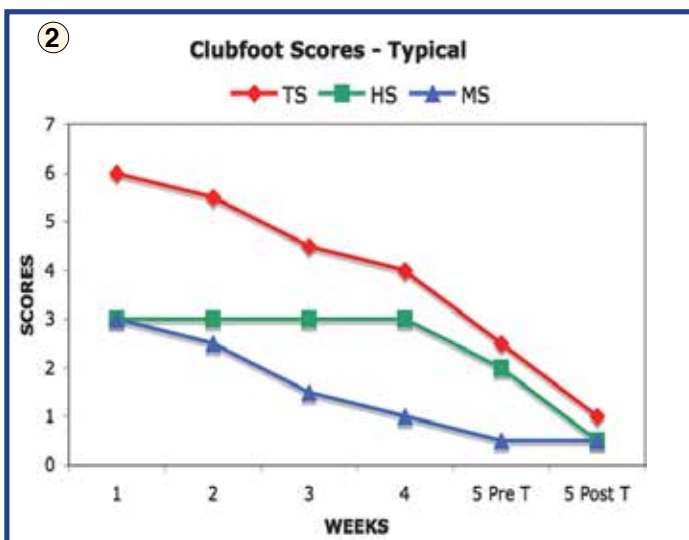
Method Use six clinical signs to quantify severity [1] of each component of the deformity. Each component is scored as 0 (normal), 0.5 (mildly abnormal) or 1 (severely abnormal). Record each score and the sum of the scores at each clinic visit.

Progress assessment During Ponseti management, the record shows whether the deformity is correcting normally [2] or whether there is a problem, and the degree of correction of each component of the clubfoot. The score also helps in deciding when to perform a heel-cord lengthening.

Source Contact Dr. Shafique Pirani for details of this scoring method at: piras@aol.com.

Dimeglio score

The Dimeglio Clubfoot Score provides an additional method of assessing each component of the clubfoot deformity. See: van Mulken JM, Bulstra SK, Hoefnagels NH. Evaluation of the treatment of clubfeet with the Diméglio score. J Pediatr Orthop. 2001 Sep-Oct;21(5):642-7.



Information for Parents

What is clubfoot?

Clubfoot is the most common deformity of the foot bones and joints in newborns. It occurs in about 1 in 1,000 babies. The cause of clubfoot is not exactly known, but it is most likely a genetic disorder and not caused by anything the parents did or did not do. Therefore, there is no reason for parents to feel guilty about having a child with clubfoot. The chances of having a second child with a clubfoot are approximately 1 in 30.

Parents of an otherwise normal infant who is born with clubfoot can be reassured that their baby, when treated by an expert in this field, will have a normal-looking foot with essentially normal function. The well-treated clubfoot causes no handicap and the individual is fully able to live a normal active life.

Starting treatment

The foot is gently manipulated for about 1 minute every week to stretch the short and tight ligaments and tendons on the inside, back, and bottom of the foot. A cast that extends from the toes to the groin is then applied. The cast maintains the correction obtained by the manipulation and relaxes the tissues for the next manipulation. In this manner, the displaced bones and joints are gradually brought into correct alignment. Treatment should begin during the first week or two of life to take advantage of the favorable elasticity of the tissues at that age.

Cast care at home

Check the circulation in the foot every hour for the first 6 hours after application and then four times a day. Gently press the toes and watch the return of blood flow. The toes will turn white and then quickly return to pink if the blood flow to the foot is good. This is called “blanching.” If the toes are dark and cold and do not blanch (white to pink), the cast may be too tight. If this occurs, go to your doctor’s office or local emergency department and ask them to check the cast. If your child has a soft roll fiberglass cast, remove it.

Note the relationship between the tips of the toes and the end of the cast If the toes seem to be shrinking back inside the cast, return to your doctor’s office or clinic for evaluation.

Keep the cast clean and dry The cast may be wiped with a slightly dampened cloth if it becomes soiled.

The cast should be placed on a pillow or soft pad until dry and hard With your child on his/her back, place a pillow under the cast to elevate the leg so that the heel extends just beyond the pillow. This prevents pressure on the heel that could cause a sore.

Prevent cast soiling by frequent diaper changes. Keep the upper end of the cast out of the diaper to prevent urine/stool from getting inside the cast. Disposable diapers and diapers with elasticized legs are ideal if available.

Notify your doctor or the clinic nurse if you notice any of the following

- Any foul-smelling odor or drainage coming from inside the cast.
- Red, sore, or irritated skin at the edges of the cast.
- Poor circulation in the toes (see #1 above).
- Cast slipping off.
- Child running a fever of 38.5°C/101.3°F or higher without an explainable reason, such as a cold or virus.

A new cast will be applied every 5 to 7 days

The cast will be removed with a special plaster knife; therefore, the cast must be softened the day you are coming to the clinic. To do this, put your child in a tub or sink, making sure that warm water is getting inside the cast (about 15–20 minutes). After the bath, wrap a soaking wet hand towel around the cast and cover with a plastic bag. A bread sack works well for this.

Duration of active treatment

Five to seven casts (each extending from the toes to the upper thigh, with the knee at a right angle), over a period of four to seven weeks, should be sufficient to correct the clubfoot deformity (see sequence below). Even very stiff feet require no more than eight or nine casts to obtain maximum correction. X-rays of the foot are not necessary, except in complex cases, because the surgeon can feel the position of the bones and the degree of correction with his/her fingers.

Completion of active treatment

A minor office procedure is required to complete the correction in most feet. The back of the ankle is made numb, either with a numbing cream or an injection, after which the heel-cord tendon is divided with a narrow scalpel. A final cast is applied. The tendon regenerates at the proper length and strength by the time the cast is removed 3 weeks later. At the end of the treatment, the foot should appear slightly over-corrected, assuming a flatfoot shape. It will return to normal in a few months.

Maintaining correction – the foot abduction brace

Clubfoot deformity tends to relapse after correction. To prevent relapses after removal of the last cast, a foot abduction brace must be worn, regardless of whether or not the heel-cord tendon was cut. There are several different types of abduction braces available. The most commonly used brace consists of straight-bordered, high-top, open-toe shoes that are attached to the ends of an adjustable aluminum bar. The distance between the heels of the shoes equals the width of the baby's shoulders. Modifications to the shoes are made to prevent them from slipping off. The shoe on the clubfoot is outwardly rotated 60 to 70 degrees and on the normal foot (if the child has only one clubfoot), 30 to 40 degrees. The brace is worn 23 hours a day for at least 3 months and, thereafter, at night and during naps for 3 to 4 years.

During the first and second nights of wearing the brace, the baby may be uncomfortable as he/she adjusts to the legs being tethered together. It is very important that the brace not be removed, because recurrence of the clubfoot deformity will almost invariably occur if the brace is not worn as prescribed. After the second night, the baby will have adapted to the brace. When not required to wear the brace, ordinary shoes can be worn.

The foot abduction brace is used only after the clubfoot has been completely corrected by manipulation, serial casting and, possibly, heel-cord tendon release. Even when well corrected, the clubfoot has a tendency to relapse until the child is approximately 4 years old. The foot abduction brace, which is the only successful method of preventing a relapse, is effective in 95% of the patients when used consistently as described above. Use of the brace will not delay the child's development with regard to sitting, crawling, or walking.

Wearing instructions for the foot abduction brace

Always use cotton socks that cover the foot everywhere the shoe touches the baby's foot and leg. Your baby's skin may be sensitive after the last casting, so you may want to use two pairs of socks for the first 2 days only. After the second day, use only one pair of socks.

If your child does not fuss when you put the brace on, you may want to focus on getting the worst foot in first and the better one in second. However, if your baby tends to kick a lot when putting on the brace, focus on the better foot first, because the baby will tend to kick into the second shoe.

Hold the foot into the shoe and tighten the ankle strap first. The strap helps keep the heel firmly down into the shoe. Do not mark the hole on the strap that you use because, with use, the leather strap will stretch and your mark will become meaningless.

Check that the child's heel is down in the shoe by pulling up and down on the lower leg. If the toes move backward and forward, the heel is not down, so you must retighten the strap. A line should be marked on the top of the insole of the shoe indicating the location of the tips of the child's toes; the toes will be at or beyond this line if the heel is in proper position.

Lace the shoes tightly but do not cut off circulation. Remember: the strap is the most important part. The laces are used to help hold the foot in the shoe.

Be sure that all of the baby's toes are out straight and that none of them are bent under. Until you are certain of this, you may want to cut the toe portion out of a pair of socks so you can clearly see all the toes.

Helpful tips for the foot abduction brace

Expect your child to fuss in the brace for the first 2 days. This is not because the brace is painful but because it is something new and different.

Play with your child in the brace. This is key to getting over the irritability that is often due to the inability of the child to move his/her legs independently of each other. You must teach your child that he/she can kick and swing the legs simultaneously with the brace on. You can gently push and pull on the bar of the brace to teach your child to flex and extend his/her knees simultaneously.

Make it routine Children do better if you make this treatment a routine in your life. During the 3 to 4 years of night and naptime wear, put the brace on any time your child goes to the “sleeping spot.” The child will know that when it is that time of day, the brace needs to be worn. Your child is less likely to fuss if you make the use of this brace a part of the daily routine.

Pad the bar Bicycle handlebar tape works well for this. By padding the bar, you will protect your child, yourself, and your furniture from being hit by the bar when the child is wearing it.

Never use lotion on any red spot on the skin. Lotion makes the problem worse. Some redness is normal with use. Bright red spots or blisters, especially on the back of the heel, usually indicate that the shoe was not worn tightly enough. Make sure that the heel stays down in the shoe. If you notice any bright red spots or blistering, contact your physician.

If your child continues to escape from the brace, and the heel is not down in the shoe, try the following.

- a. Tighten the strap by one more hole.
- b. Tighten the laces.
- c. Remove the tongue of the shoe (use of the brace without the tongue will not harm your child).
- d. Try lacing the shoes from top to bottom, so that the bow is by the toes.

Periodically tighten the screw on the bar.

Long term monitoring

Following full correction of the clubfoot, clinic visits will be scheduled every 3–4 months for 2 years, and then less frequently. Your physician will decide on the duration of bracing depending upon the severity of the clubfoot and the tendency for the deformity to relapse. Do not end treatment early. Yearly visits will be scheduled for 8 to 10 years to check for possible long-term relapses.

Relapses

If the deformity relapses during the first 2–3 years, weekly manipulations and casts are reinstituted. Occasionally, a second heel-cord tendon release is needed. In some cases, despite proper bracing, a minor operation is needed when the child is older than 3 years to prevent further relapses. The operation consists of transferring a tendon (the tibialis anterior) from the inside border of the foot to the center of the foot.

Bibliography

- 1963** Ponseti IV, Smoley EN. Congenital clubfoot: the results of treatment. *J Bone Joint Surg Am* 45(2):2261–2270.
- 1966** Ponseti IV, Becker JR. Congenital metatarsus adductus: the results of treatment. *J Bone Joint Surg Am* 43(4):702–711.
- 1972** Campos J, Ponseti IV. Observations on pathogenesis and treatment of congenital clubfoot. *Clin Orthop Relat Res* 84:50–60.
- 1974** Ionasescu V, Maynard JA, Ponseti IV, Zellweger H. The role of collagen in the pathogenesis of idiopathic clubfoot: biochemical and electron microscopic correlations. *Helv Paediatr Acta* 29(4):305–314.
- 1980** Ippolito E, Ponseti IV. Congenital clubfoot in the human fetus: a histological study. *J Bone Joint Surg Am* 62(1):8–22.
- 1980** Laaveg SJ, Ponseti IV. Long-term results of treatment of congenital clubfoot. *J Bone Joint Surg Am* 62(1):23–31.
- 1981** Brand RA, Laaveg SJ, Crowninshield RD, Ponseti IV. The center of pressure path in treated clubfoot. *Clin Orthop Relat Res* 160:43–47.
- 1981** Ponseti IV, El-Khoury GY, Ippolito E, Weinstein SL. A radiographic study of skeletal deformities in treated clubfoot. *Clin Orthop Relat Res* 160:30–42.
- 1992** Ponseti IV. Treatment of congenital clubfoot. [Review, 72 refs] *J Bone Joint Surg Am* 74(3):448–454.
- 1994** Ponseti IV. The treatment of congenital clubfoot. [Editorial] *J Orthop Sports Phys Ther* 20(1):1.
- 1995** Cooper DM, Dietz FR. Treatment of idiopathic clubfoot: a thirty-year follow-up note. *J Bone Joint Surg Am* 77(10):1477–1489.
- 1996** Ponseti IV. *Congenital Clubfoot: Fundamentals of Treatment*. Oxford University Press.
- 1997** Ponseti IV. Common errors in the treatment of congenital clubfoot. *Int Orthop* 21(2):137–141.
- 1998** Ponseti IV. Correction of the talar neck angle in congenital clubfoot with sequential manipulation and casting. *Iowa Orthop J* 18:74–75.
- 2000** Ponseti IV. Clubfoot management. [Editorial] *J Pediatr Orthop* 20(6):699–700.
- 2001** Pirani S, Zeznik L, Hodges D. Magnetic resonance imaging study of the congenital clubfoot treated with the Ponseti method. *J Pediatr Orthop* 21(6):719–726.
- 2003** Ippolito E, Farsetti P, Caterini R, Tudisco C. Long-term comparative results in patients with congenital clubfoot treated with two different protocols. *J Bone Joint Surg Am* 85(7):1286–1294.
- 2003** Morcuende JA, Egbert M, Ponseti IV. The effect of the internet in the greatment of congenital idiopathic clubfoot. *Iowa Orthop J* 23:83–86.
- 2004** Morcuende JA, Dolan L, Dietz F, Ponseti IV. Radical reduction in the rate of extensive corrective surgery for clubfoot using the Ponseti method. *Pediatrics* 113:376–380.
- 2004** Dobbs MB, Rudzki JR, Purcell DB, Walton T, Porter KR, Gurnett CA. Factors predictive of outcome after use of the Ponseti method for the treatment of idiopathic clubfeet. *J Bone Joint Surg Am* 86(1):22–27.
- 2005** Morcuende JA, Abbasi D, Dolan LA, Ponseti IV. Results of an accelerated Ponseti protocol for clubfoot. *J Pediatr Orthop* 25(5):623–626.
- 2005** Tindall AJ, Steinlechner CW, Lavy CB, Mannion S, Mkandawire N. Results of manipulation of idiopathic clubfoot deformity in Malawi by orthopaedic clinical officers using the Ponseti method: a realistic alternative for the developing world? *J Pediatr Orthop* 25:627–629.
- 2005** Konde-Lule J, Gitta S, McElroy T and the Uganda Sustainable Clubfoot Care Project. *Understanding Clubfoot in Uganda: A Rapid Ethnographic Study*. Makerere University.
- 2006** Dobbs MB, Nunley R, Schoenecker PL. Long-term follow-up of patients with clubfeet treated with extensive soft-tissue release. *J Bone Joint Surg Am* 88:986–996.
- 2006** Ponseti IV, Zhivkov M, Davis N, Sinclair M, Dobbs MB, Morcuende JA. Treatment of the complex idiopathic clubfoot. *Clin Orthop Relat Res* 451:171–176.
- 2006** Shack N, Eastwood DM. Early results of a physiotherapist-delivered Ponseti service for the management of idiopathic congenital talipes equinovarus foot deformity. *J Bone Joint Surg Br* 88:1085–1089.
- 2007** McElroy T, Konde-Lule J, Neema S, Gitta S; Uganda Sustainable Clubfoot Care. Understanding the barriers to clubfoot treatment adherence in Uganda: a rapid ethnographic study. *Disabil Rehabil* 29:845–855.
- 2007** Lourenço AF, Morcuende JA. Correction of neglected idiopathic club foot by the Ponseti method. *J Bone Joint Surg Br* 89:378–381.
- 2007** Terrazas-Lafargue G, Morcuende JA. Effect of cast removal timing in the correction of idiopathic clubfoot by the Ponseti method. *Iowa Orthop J* 27:24–27.
- 2008** Morcuende JA, Dobbs MB, Frick SL. Results of the Ponseti method in patients with clubfoot associated with arthrogyriposis. *Iowa Orthop J* 28:22–26.
- 2008** Gurnett CA, Boehm S, Connolly A, Reimschisel T, Dobbs MB. Impact of congenital talipes equinovarus etiology on treatment outcomes. *Dev Med Child Neurol*. 2008 Jul;50(7):498–502.
- 2008** Richards BS, Faulks S, Rathjen KE, Karol LA, Johnston CE, Jones SA. A comparison of two nonoperative methods of idiopathic clubfoot correction: the Ponseti method and the French functional (physiotherapy) method. *J Bone Joint Surg Am*. 2008 Nov;90(11):2313–21.

Global HELP Organization rapidly accumulating publications are freely available on our web-site or printed and available at minimal cost. Please visit our web-site at www.global-help.org. This publication, originally created in English, is now in use in over 140 countries and is being trans-lated into numerous languages.

Publications

All publications from our web-site are free. Publications are available in several forms.

PDF for Web site and CD libraries

All publications are available in PDF format. PDF files can be downloaded from our web-site by clicking on the publication title or image. These files are then copied on your computer and can be printed on personal printers in color or black-and-white. CD libraries include many publications in one convenient compact disc. Some CD libraries are restricted to be used only in developing countries.

Printed publications

Some publications are available for “on demand” printing. Order single or multiple printed copies on our web-site at www.global-help.org. These publications are available for only the cost of printing and mailing.

Web site address:
www.global-help.org

questions@global-help.org

ISBN 978-1-60189-002-3



Copyright © 2009 Global HELP
all rights reserved



GLOBAL HELP
HEALTH EDUCATION USING LOW-COST PUBLICATIONS
WWW.GLOBAL-HELP.ORG