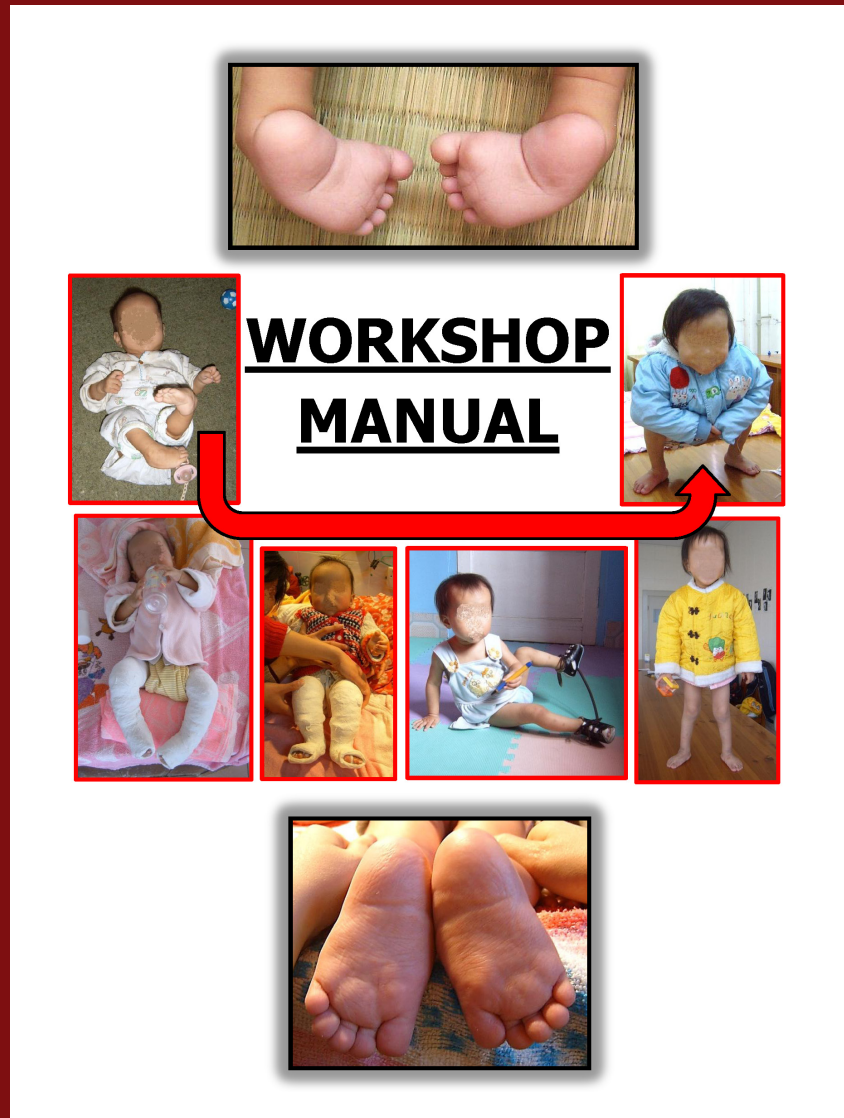


# Treatment Of Congenital Clubfoot Using The Ponseti Method

Workshop Manual

[2nd Edition]



Iris Lohan



GLOBAL HELP  
HEALTH EDUCATION USING LOW-COST PUBLICATIONS

# **FOREWORD**

This 2<sup>nd</sup> edition of the workshop manual is primarily designed for attendees of training workshops in China, helping them to understand what Congenital Clubfoot is, grasp the Ponseti method of Clubfoot treatment and get helpful advice. Of course I would like to see it used in lots of other countries as well. It should serve as a reference book when questions occur and I hope it will be a very practical and helpful guide for practitioners using the Ponseti technique. I have endeavoured to use drawings to make very clear the correct hand positions for manipulation and casting. Over the years I gained more experience in the treatment and encountered challenges especially in older children and children with other health issues associated with Clubfoot. With this 2<sup>nd</sup> edition I aim to improve the quality by corrections, changes and additions. I strongly recommend physiotherapy, combined with the Ponseti management when the child starts wearing the abduction brace.

This manual provides a "Congenital Clubfoot assessment and treatment record" ([Appendix 1](#)) and also contains "Information for parents" ([Appendix 2](#)) to help the parents understand their child's condition, the treatment, and their very important role and responsibility in the treatment. I added a "Doctor's check up sheet" ([Appendix 3](#)) and a "Parent's instruction sheet" ([Appendix 4](#)). These four appendices are designed for making copies for the use of every child's treatment.

I want to express my thanks to Drs Marc Sinclair and Norgrove Penny who taught the Ponseti method at two Clubfoot courses in Guilin, China in May 2004, where I was able to learn this method of treatment. I am also very thankful to Dr Jose Morcuende for your visit in Guilin in September 2005, your advice and help via email, and for responding to a lot of questions concerning the treatment of children with Clubfoot in China.

A special thank you, Xiaoyan, for your invaluable assistance in helping to teach and translate at Clubfoot workshops in China, and all the translation work for the Chinese manual. You are a treasure. Karen, the idea of making drawings of the foot movements has been quite helpful for me. Thanks. Thank you, Brian and Angela, for all the corrections of my "German English". Tony and Andreas, thanks a lot for your help with the arrangements of text and images on the computer. Guorong, Carolyn and Peggy, thank you for all the translation work for the 2<sup>nd</sup> edition. Yuan, thank you so much for your corrections in the Chinese 2<sup>nd</sup> edition.

**May this manual serve thousands of children with Clubfoot and their families  
- to change their lives forever!**

Iris Lohan (罗伊乐)  
Physiotherapist  
iris.lohan@gmail.com



# **REFERENCES**

- 1) Congenital Clubfoot, Fundamentals of treatment: Ignacio v. Ponseti, Oxford University Press
- 2) Clubfoot: Ponseti Management: various authors, Editor: Lynn Staheli MD, Global-HELP Publication
- 3) The Ponseti method of Clubfoot Manipulation, Workshop Manual: prepared by Shafique Pirani, MD and Norgrove Penny, MD
- 4) Dtv-Atlas der Anatomie. Bewegungsapparat Band 1: Werner Platzer Deutscher Taschenbuchverlag und Georg Thieme Verlag
- 5) Funktionelle Anatomie der Gelenke. Band 2. Untere Extremität: I.A. Kapandji. Ferdinand Enke Verlag
- 6) Treatment of Complex Idiopathic Clubfoot: Ignacio V. Ponseti, MD; Miroslav Zhivkov, MD; Naomi Davis, FRCSEd; Marc Sinclair, MD; Matthew B. Dobbs, MD; Jose A. Morcuende, MD, PhD), CLINICAL ORTHOPAEDICS AND RELATED RESEARCH Number 0, pp.000-000
- 7) Articles found at "Ponseti International Association" ([www.ponseti.info](http://www.ponseti.info))
- 8) Der kleine Fuß ganz groß, Barbara Zukunft-Huber, Elsevier Urban&Fischer
- 9) Funktionelle Anatomie des Menschen, Johannes W. Rohen, Schattauer

# **TABLE OF CONTENTS**

<b>FOREWORD AND REFERENCES .....</b>	<b>1</b>
<b>CONGENITAL CLUBFOOT AND THE PONSETI TREATMENT IN CHINA .....</b>	<b>3 - 4</b>
<b>ANATOMY AND MOVEMENTS OF THE FOOT</b>	
The foot bones .....	5
The foot segments .....	6
The movements of the foot .....	7 - 8
<b>KINEMATIC COUPLING OF MID FOOT AND HEEL .....</b>	<b>9</b>
<b>PATHOANATOMY OF CONGENITAL CLUBFOOT .....</b>	<b>10 - 11</b>
<b>ASSESSMENT, EXAMINATIONS, SCORING</b>	
Assessment, examination, check up and documentation .....	12
Pirani severity scoring .....	14
Pirani scoring signs .....	15 - 17
<b>PONSETI TREATMENT</b>	
Overview of CF treatment using the Ponseti method (basic guideline) .....	18
Early CF treatment start using the Ponseti method ( guideline "younger child").	19
Later CF treatment start using the Ponseti method (guideline "older child") .....	20
Manipulation .....	21 - 22
Hand positions for manipulation .....	23 - 24
Casts after manipulations .....	25 - 27
Hand positions for casting .....	28 - 30
Casts removal .....	31
Percutaneous tenotomy of the Achilles tendon .....	32 - 33
The bracing .....	34 - 36
<b>RECURRENCES AND THEIR MANAGEMENT .....</b>	<b>37 - 39</b>
<b>COMMON ERRORS TO AVOID .....</b>	<b>40</b>
<b>THE PARENTS .....</b>	<b>41</b>
<b><u>APPENDICES: Please copy and use appendices 1- 4</u></b>	
<b>Appendix 1: Congenital Clubfoot assessment and treatment record .....</b>	<b>42 - 43</b>
<b>Appendix 2: Information for parents .....</b>	<b>44 - 48</b>
<b>Appendix 3: Doctor`s check up sheet .....</b>	<b>49</b>
<b>Appendix 4: Parent`s instruction sheet .....</b>	<b>50</b>
<b>Appendix 5: Atypical Clubfoot .....</b>	<b>51 - 53</b>
<b>Appendix 6: Congenital CF associated with other defects and after surgery</b>	<b>54</b>
<b>Appendix 7: Links relating to the Ponseti method; treatment examples.....</b>	<b>55</b>

# **CONGENITAL CLUBFOOT**

## **AND THE PONSETI TREATMENT**

### **IN CHINA**

#### **1. Information about Congenital Clubfoot**

- **Congenital Clubfoot is Clubfoot present at birth.**
- **Clubfoot is one of the most common congenital deformities.**  
About 1 in every 1000 children is born with clubfoot worldwide.
- **Congenital Clubfoot is a developmental deformation:**  
A normal developing foot turns into a Clubfoot around the 3<sup>rd</sup> month of foetal life. Etiological factors for the development of the deformity seem to be active for several years explaining relapses after correction. The aetiology is not exactly known, but is believed that genetic and extrinsic factors are involved. Fibrosis, meaning a pathological increase of connective tissue, seems to be the main reason leading to the deformity. At the posterior and medial aspects of Clubfeet, shorter muscles and increased tissue in muscles, fasciae, ligaments, tendons and tendon sheaths had been found.
- **Hereditary transmission:**  
One parent affected by Congenital Clubfoot: about 3-4% chance to transmit to the child.  
Both parents affected by Congenital Clubfoot: about 15% chance to transmit to the child.
- **More in boys than in girls**
- **Bilateral (both feet) or unilateral (one foot)**
- **Alone or in association with** neuromuscular diseases, chromosomal abnormalities, syndromes and other congenital abnormalities like:  
Arthrogryposis Multiplex Congenita (AMC), Myelomeningocele (MMC),  
Larsen Syndrome, Diastrophic Dysplasia, Moebius Syndrome, Amniotic Band Syndrome, Metatarsus Adductus, Limb deformities like Syndactyly, missing toes, extra toes.  
For details see [Appendix 6](#).

#### **2. Why use the Ponseti method for Clubfoot treatment in China?**

- Clubfoot children are often abandoned or face a future in poverty.  
By correcting their feet, they get the opportunity to live a normal life.
- The Ponseti method is a very effective and relatively inexpensive treatment with good long term results.
- Medical workers of a lower level can learn the manipulation and casting technique as well as orthopaedic surgeons.
- Surgeons report that Clubfeet treated by surgical methods become weak, stiff and are often painful in adult life.

### **3. Goal and result of the Ponseti treatment**

- The goal is to reduce if not eliminate all elements of the Clubfoot deformity to obtain a functional, flexible, pain free, strong, normal looking, plantigrade and normal shoeable foot.
- In general the success rate (in babies without other health issues) can be expected to be 95+%.
- The treatment result depends on:
  - a. Severity of the Clubfoot.
  - b. Involvement of other health issues (e.g. neuromuscular disease, syndrome).
  - c. Age and physical development stage of the child at treatment start.
  - d. Experience of the doctor/health care worker.
  - e. Cooperation of the parents.
  - f. Brace compliance.
- Minor differences may be noticed in a successfully treated Clubfoot:
  - a. The Clubfoot is slightly smaller (shorter, narrower) than the other foot.
  - b. A smaller circumference of the lower leg.
  - c. Shorter calf muscles.

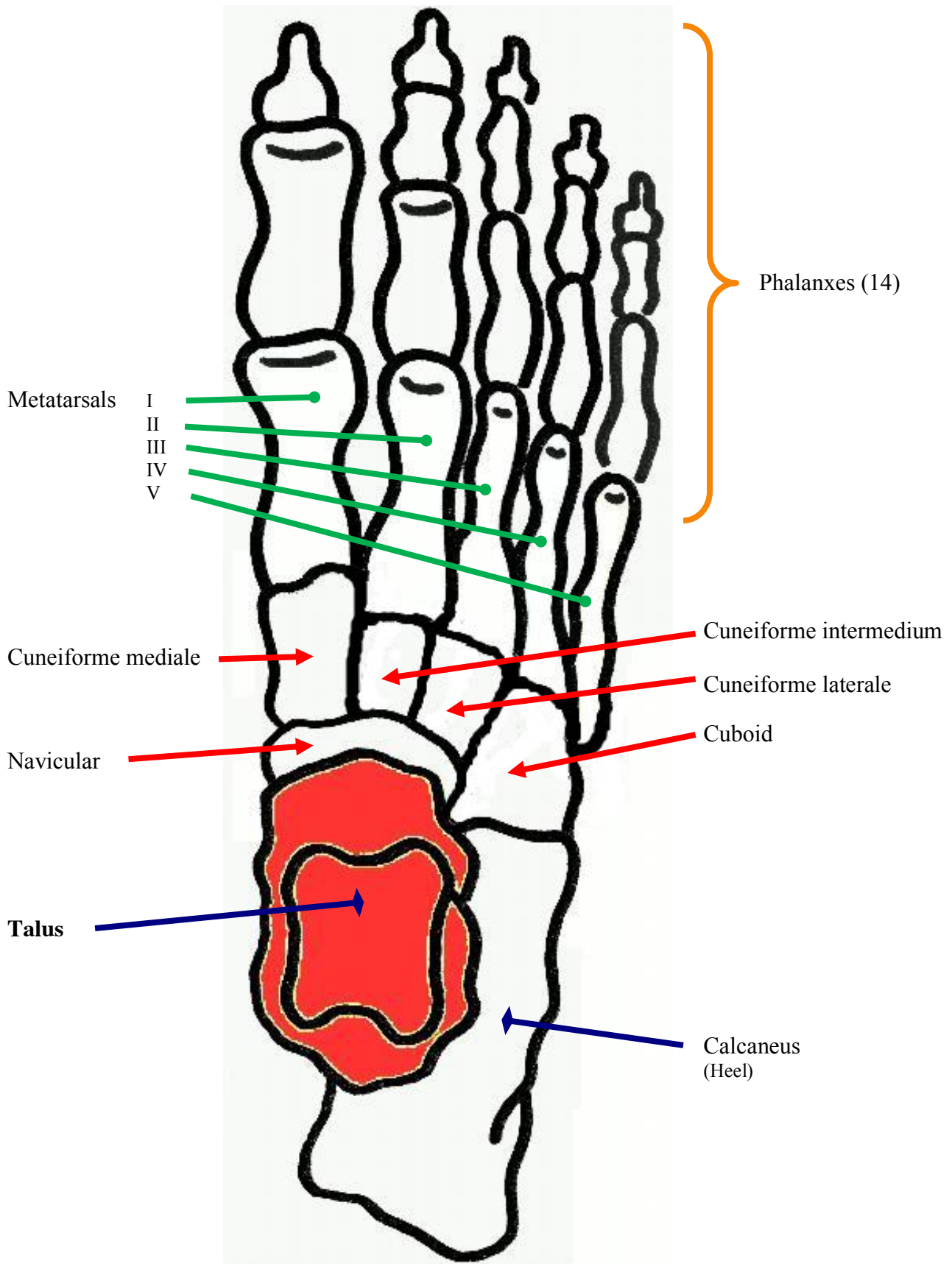
### **4. When to start the Ponseti treatment?**

- |   |  |
|---|--|
| • Soon after birth (~7-10 days):            | <b><u>The best</u></b>   |
| • Not yet walking child:                    | <b><u>Very effective</u></b>   |
| • Walking child up to several years of age: | <b><u>Effective</u></b> in correcting all or much of the deformity. Depending on severity and other associated health issues, older children may require additional surgery. |

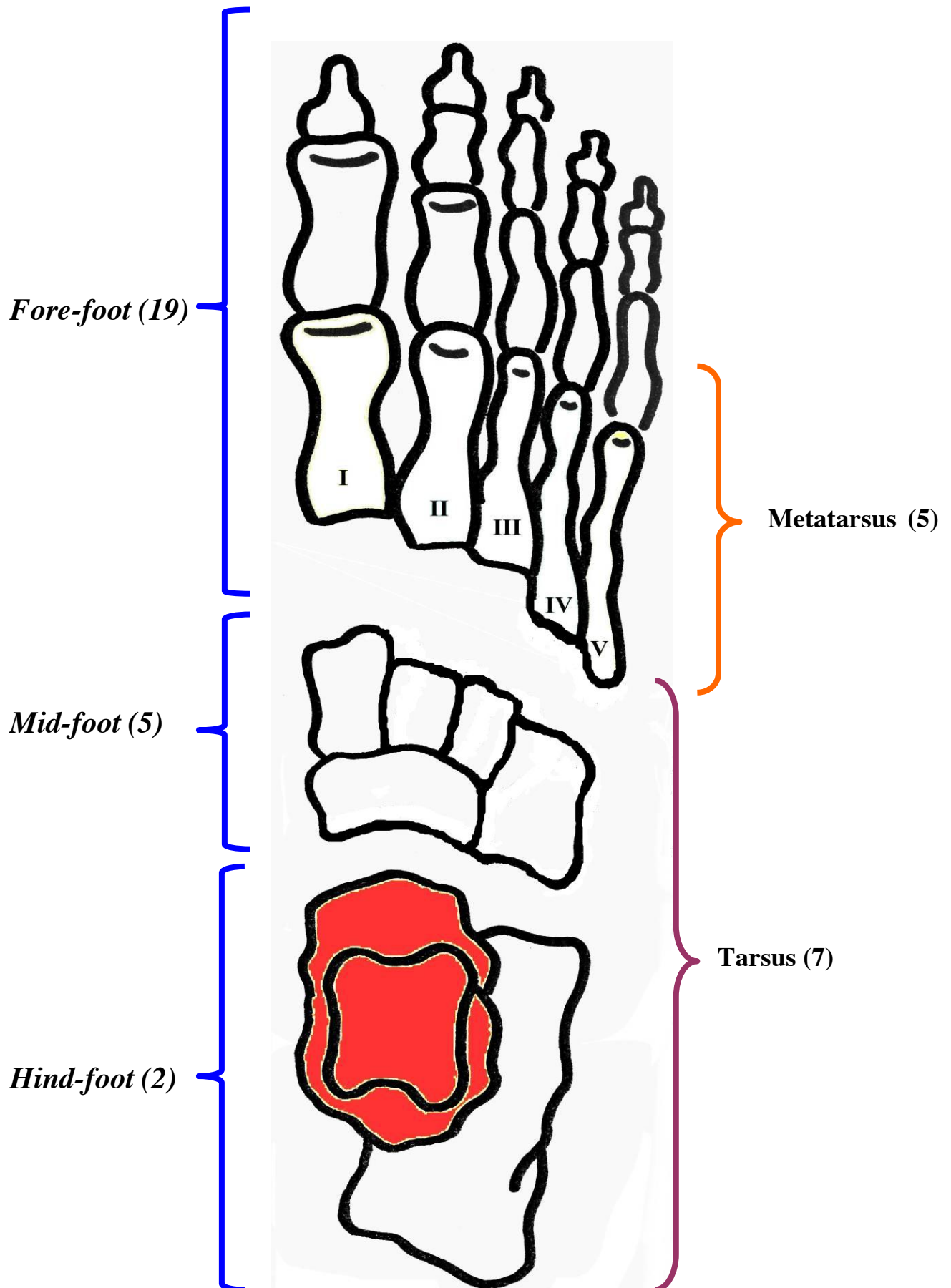
### **5. Long term goals for China**

- **Raise the awareness** of Congenital Clubfoot and the need for early effective treatment among the Chinese people. Doctors, midwives and nurses in hospitals, social welfare institutes and even in small clinics should be informed as well as medical students by lectures and newsletters. Every part of the society but especially young couples should be addressed in every part of China. This can be done through posters, newspapers, television and internet.
- **Build consensus** that the Ponseti method is an effective treatment for Congenital Clubfoot.
- **Build capacity to treat Congenital Clubfoot** by providing training.
- **No neglected Clubfoot in China in the future.**

## THE FOOT BONES (26)



## THE FOOT SEGMENTS



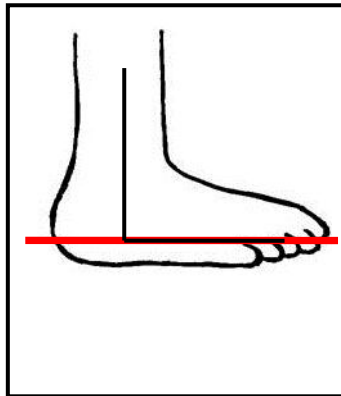
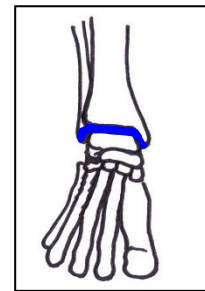
# THE MOVEMENTS OF THE FOOT

## 1. Ankle joint

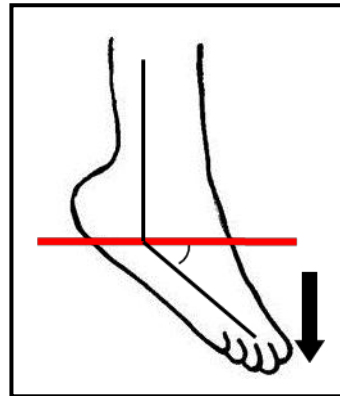
The ankle joint connects the lower leg and upper foot and is formed by the Talus in correspondence with distal parts of Tibia and Fibula.

The possible movements are:

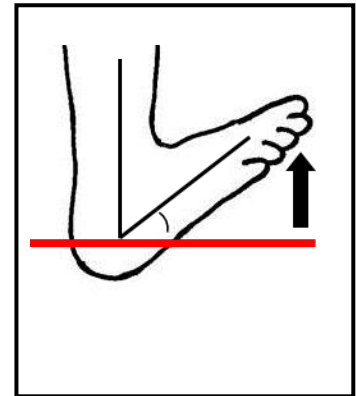
- Plantar flexion (30-50°)
- Dorsiflexion (20-30°)



**Neutral position**



**Plantar flexion**



**Dorsiflexion**

Muscles for Plantar flexion are Triceps surae, Peroneus longus, Peroneus brevis, Flexor digitorum longus and Tibialis posterior. Muscles for Dorsiflexion are Tibialis anterior, Extensor digitorum longus and Extensor hallucis longus.

## 2. Tarsal joints

Three tarsal joints are mainly responsible for the subtalar movements of the mid foot and the heel and work together as a unit, but there are other joint connections involved also.

1. Talo-calcaneo joint = Subtalar joint (posterior part):

2. Talo-calcaneo-navicular joint (anterior part):

The plantar Calcaneo-navicular ligament serves as part of the joint giving support to the head of the Talus.

3. Calcaneo-cuboid joint (amphiarthrosis)

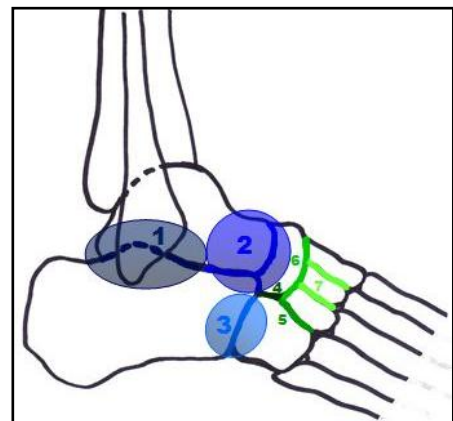
The other tarsal joints are:

4. Navicular-cuboid joint

5. Cuboid-cuneiforme laterale joint

6. Navicular-cuneiforme joint(s) (3 parts )

7. 2 Inter-cuneiforme joints



**Functionally, all tarsal bones (Navicular and Calcaneus directly) move simultaneously as a unit around the Talus.**

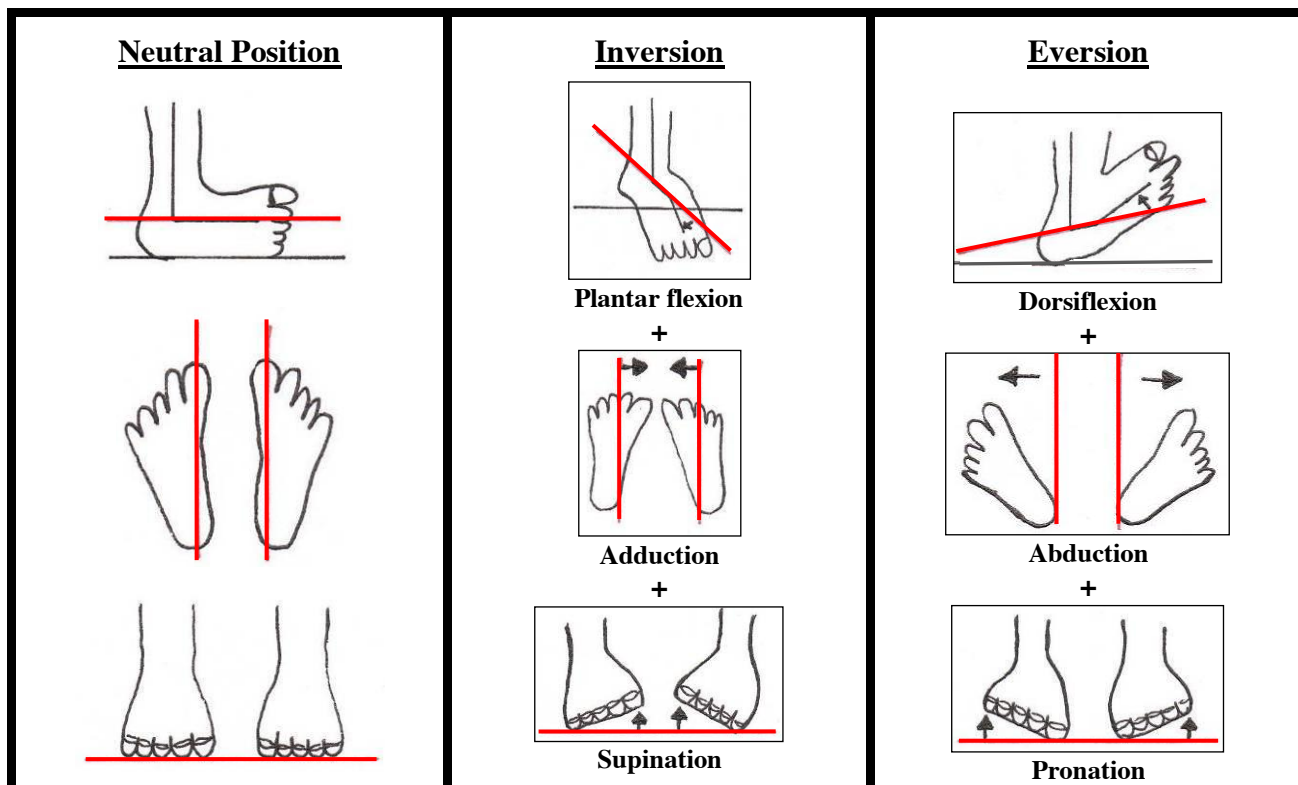
The definitions of movements in the foot are quite confusing in medical literature, so I will clarify the terminology I use with the following illustrations and explanations. Lots of muscles are involved to move the foot in the tarsal joints three dimensional. I only want to mention Tibialis posterior (plantar flexor, supinator, adductor), Tibialis anterior (dorsal flexor, supinator), Peroneus longus (pronator, plantar flexor, abductor), Flexor hallucis longus (flexor of 1<sup>st</sup> toe, supinator) and Flexor digitorum longus (flexor of 2<sup>nd</sup> to 5<sup>th</sup> toe, plantar flexor, supinator, adductor) which have important roles for the arch of the foot.

## 2a) Movements of the Mid foot

The possible movements of the mid foot are Plantar flexion and Dorsiflexion (both directions only a little bit), Adduction and Abduction, Supination and Pronation.

Inversion is the combined movement of Plantar flexion, Adduction and Supination.

Eversion is the combined movement of Dorsiflexion, Abduction and Pronation.

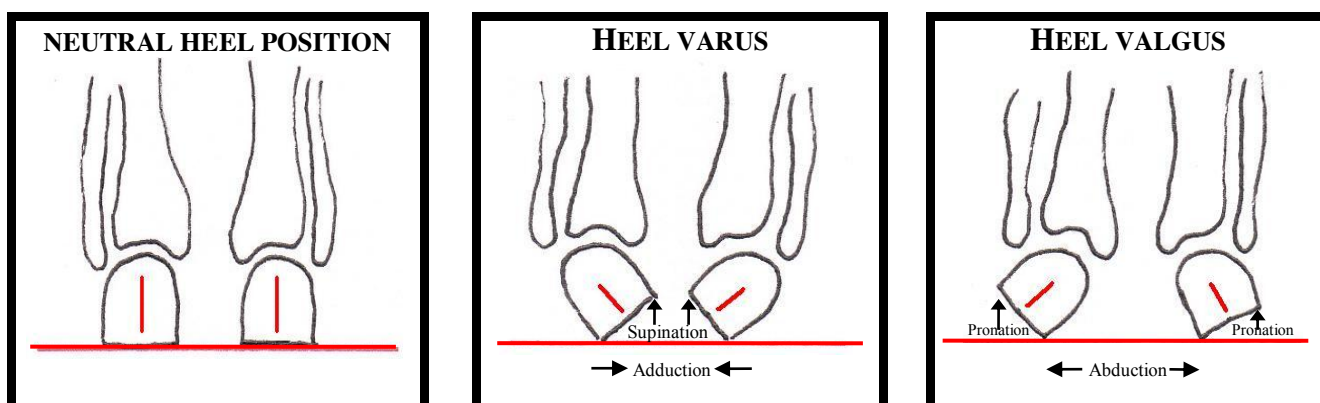


## 2b) Movements of the Heel

Movements in the tarsal joints change the position of the heel, which is the Calcaneus. The position can be seen by watching from the back.

If the Calcaneus "lays down" in direction of the lateral part it is called Heel Varus, which means Supination and Adduction of the Calcaneus. I suspect Plantar flexion of the Calcaneus as part of a three dimensional movement as well.

If the Calcaneus "lays down" in direction of the medial part it is called Heel Valgus, which means Pronation and Abduction of the Calcaneus. I suspect Dorsiflexion of the Calcaneus as part of a three dimensional movement as well.



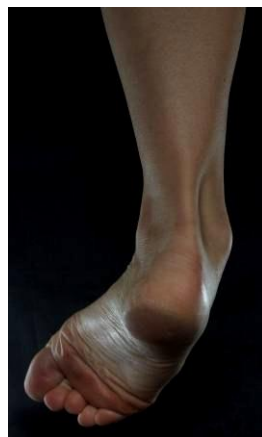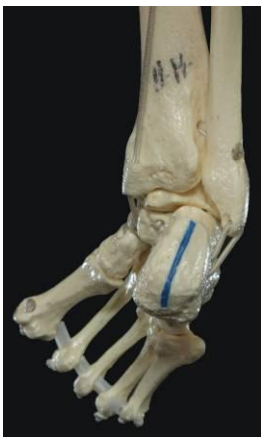## **KINEMATIC COUPLING** **OF MID FOOT AND HEEL (CALCANEUS)**

The understanding of the functional anatomy of the Tarsus is an important basic for the correction of Congenital Clubfoot using the Ponseti method.

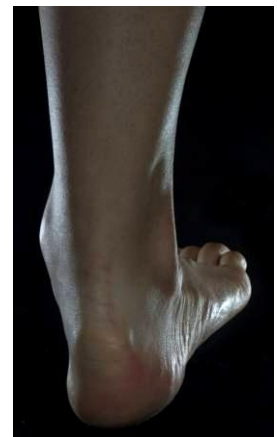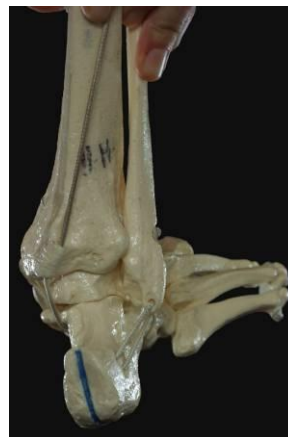The Tarsus with its 7 bones has a very complex structure and it is not possible to have only one movement between two of their bones. One initiated movement is followed by a chain reaction and causes coupled movements.

**A foot's Mid foot movement is always coupled with its Heel movement:**

**Mid foot Inversion**  
**(Plantarflex+Add+Sup)**  
**+**  
**Heel Varus**



**Mid foot Eversion**  
**(Dorsiflex+Abd+Pron)**  
**+**  
**Heel Valgus**



When the mid foot is moved into Inversion, the heel automatically moves into Heel Varus.  
When the mid foot is moved into Eversion, the heel automatically moves into Heel Valgus.

Congenital Clubfoot is a fixed position in Mid foot Inversion and Heel Varus.

In Clubfoot treatment, kinematic coupling is used to correct the Heel Varus. The Heel Varus in practice will be corrected by using the Abduction of the mid foot as an initiator to correct the Mid foot Inversion and at the same time let the heel slide in Valgus direction.

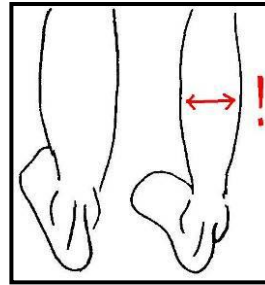
**It is very important to understand the kinematic coupling of mid foot and heel, because the Ponseti method of Clubfoot treatment is based on this principle.**

# PATHOANATOMY OF CONGENITAL CLUBFOOT

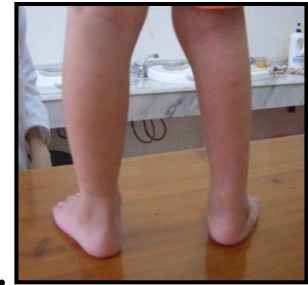## – CLUBFOOT SIGNS –

### 1. Calf is smaller

- Shorter and smaller muscle tendon unit of Triceps surae (= Gastrocnemius, Soleus, Plantaris), Tibialis posterior and toe flexor muscles.



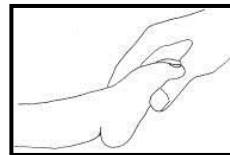
1.



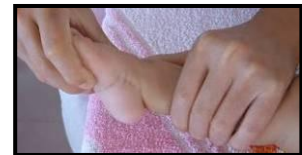( already treated )

### 2. Hind foot Equinus

- Severe Plantar flexion in the ankle joint.
- High Calcaneus (not in the heel pad).
- Talus in severe Flexion.

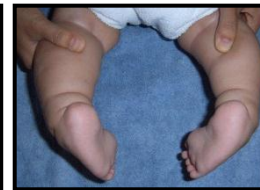


2.

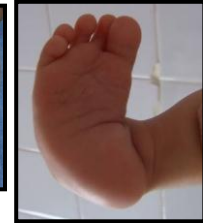


### 3. Heel in Varus

- Supination and Adduction of the Calcaneus.
- Calcaneus is locked under the Talus.



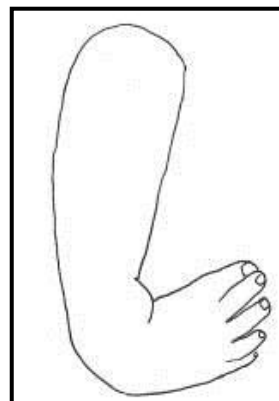
3.



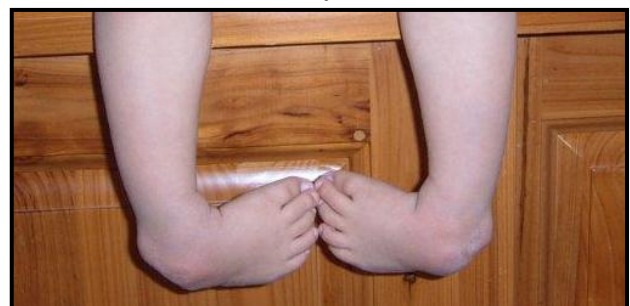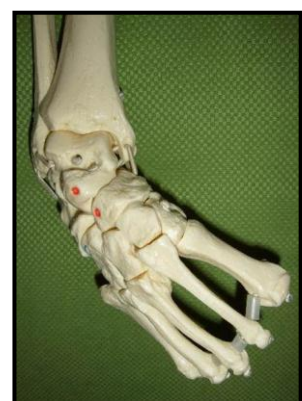### 4. Inversion of the Mid foot

(Inversion = Plantar flexion + Add + Sup)

- Navicular is medially displaced, adducted and supinated in relation to the Talus.
- Navicular articulates only with the medial part of the head of the Talus.
- Lateral part of the head of the Talus is uncovered.
- Navicular approaches the medial Malleolus.
- Cuboid is medially displaced and adducted.
- Cuneiforms (3) are downward and medially displaced in relation to the Navicular.
- Ligaments and tendons (posterior, medial) hold the foot in the wrong position.

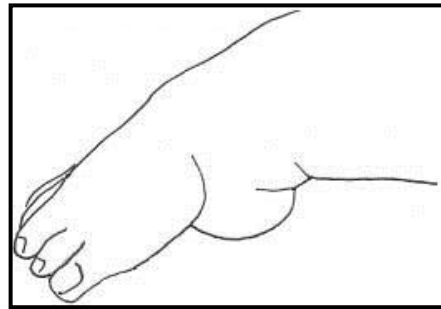


4.

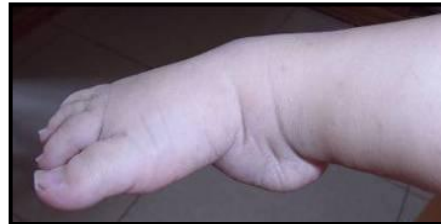

## **5. Cavus**

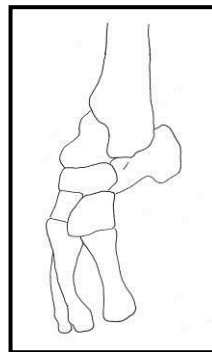
- Increase in the height of the medial arch of the foot = "break" in the foot sole plane: the forefoot in relation to the mid foot is in Pronation.
- Mid foot strong Supination and forefoot less Supination.



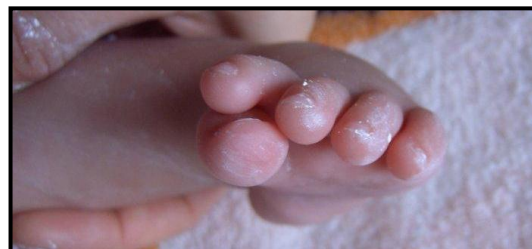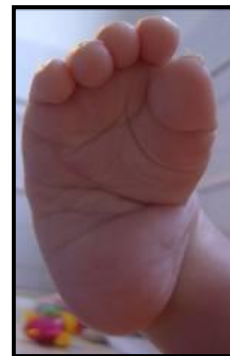
5.



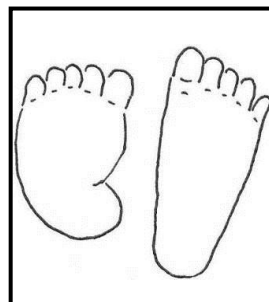
## **6. Metatarsal I is more in Plantar flexion than the rest of the Metatarsals.**



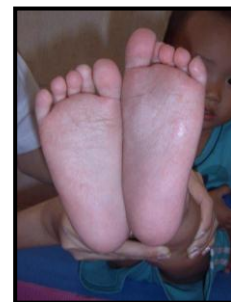6.



## **7. Clubfoot is smaller than a normal foot.**



7.



( already treated )

# **ASSESSMENT, EXAMINATION, CHECK UP AND DOCUMENTATION**

- **Papers for treatment : [Appendices 1 – 4](#)**

- **[Appendix 1](#)** “Congenital Clubfoot assessment and treatment record”
- **[Appendix 2](#)** “Information for parents”
- **[Appendix 3](#)** “Doctor’s check up sheet ”
- **[Appendix 4](#)** “Parent’s instruction sheet”

All above mentioned papers can be copied and prepared for the treatment of every child. Clear documentation is a helpful tool for a successful treatment as well as for prevention and early recognition of a recurrence.

- **Initial Assessment**

**[Appendices 1+ 2](#)**

1. **Check the feet for Clubfoot signs.**  
Clarify first, if the child really has Congenital Clubfoot or a different deformity!  
Never treat a simple Metatarsus Adductus like Clubfoot!!!
2. **Begin the assessment with general information and history. ([Appendix 1](#))**
3. **Evaluate the Clubfoot by checking the Pirani scoring signs. ([Appendix 1](#))**
4. **Examine the whole body of the child for other deformities/problems. ([Appendix 1](#))**

When examining a child, try to prepare a quiet and relaxed atmosphere for the child and the parents. The examination of the feet can be done on the mother’s lap, where the child feels safe. It is ok for the child to drink a bottle or play with a toy. Talk to the child and parents in a friendly manner while checking the feet.

The initial assessment should include the whole body (spine, hips etc.). For that, fully undress the child and lay them on the examination table.

Before starting the treatment explain to the parents what Congenital Clubfoot is and give an overview on the treatment. Hand them the “Information for parents” sheet ([Appendix 2](#)) and emphasize, that their cooperation by following the instructions is crucial for the outcome of their child’s treatment. After the first cast is applied, give them the main instructions verbally, of how to deal with the child in the cast and tell them to read the “Information for parents” for more details.

- **Examination during the correction phase**

**[Appendix 1](#)**

1. **Check the Pirani scoring signs.**  
After removing the casts do the scoring and document it ([Appendix 1](#)).
2. **Check the heel position.**
3. **Look for pressure sores or skin problems.**

- **Check up during the bracing phase**

**Appendices 1 + 3 + 4**

When Clubfoot is corrected and children have to wear the brace to prevent a recurrence, regular check ups and instructions for the parents are very important. The children's feet have to be checked regularly to ensure that any relapse is recognized very early and action can be taken to correct the feet again.

To obtain a good result of the feet, the brace should be worn at least till the age of 4. If a child struggles significantly with the brace after 2 years and the feet look fine it is possible to stop the bracing, but the child must come regular for check ups.

Always tell the parents, that they should return immediately if a foot turns back, if they discover a pressure sore or if the brace gets too small or is broken.

**1. Check the Pirani scoring signs and document it (Appendix 1).**

**2. Check the feet, the brace and ask parents if there are problems (Appendix 3).**

Check and (if applicable) fill in the following details:

- a) Problems reported by parents
- b) Pirani Total Score (TS)
- c) Range of motion (ROM) of the foot – especially Dorsiflexion and Abduction:
  - Passive: Feel the resistance and recognize limitations.
  - Active: Observe the smaller child's foot movement in different positions and when changing positions. Let the older child sit on a chair with legs hanging to move the foot actively in all directions.
- d) Heel position
  - In a not walking child check when lying on the tummy.
  - In a walking child let the child stand and check from standing behind.
- e) Active squatting
  - Check if Dorsiflexion is sufficient and on both sides the same.
  - Check the positions of the feet.
- f) Active standing:
  - Standing in normal position.
  - Standing on toes.
  - Standing on heels.
- g) Walking:
  - Swing phase: – Active Supination too much?
  - Stance phase: – Weight bearing too much lateral?
  - Heel rise: – Heel rise too early?
- h) Jumping
- i) Brace:
  - Brace size (correct?) and condition (broken parts?)
  - Check if the feet fit well in the brace.
- j) Skin: Look for red spots or pressure sores.
- k) Measure the length of both feet.

**3. Give instructions to the parents, make a new appointment for the next check up and document it (Appendix 3 + 4).**

- **Check up after the bracing phase**

**Appendices 1 + 3 + 4**

See the child until skeletal maturity. Check the Pirani scoring signs (Appendix 1), range of motion, heel position, standing, walking and jumping. Treat a relapse immediately, give helpful instructions to the parents and document it (Appendix 3 + 4).

# **PIRANI SEVERITY SCORING**

## **– Evaluation System –**

It is helpful to use this scoring system and document the results every time the feet are examined: before the treatment, during the correction phase, during the bracing phase and at later check ups ([Appendix 1+3](#)).

### **a) Reasons for using the scoring**

1. Shows the severity of the Clubfoot.
2. Encourages intensive examination in the beginning.
3. Helps to monitor treatment progress.
4. Shows, when tenotomy of the Achilles tendon is indicated.
5. Tells, when the correction is finished and the bracing should start.
6. Help for research.

### **b) General principle of scoring**

- 6 clinical signs of a Clubfoot are compared to a normal foot.
- 3 signs evaluate the Hind Foot Contracture (HFC).
- 3 signs evaluate the Mid Foot Contracture (MFC).
- Each sign is scored with:
  - 0 = no abnormality
  - 0.5 = moderate abnormality
  - 1 = severe abnormality
- Higher score indicates a more severe deformity.
- Scoring should be done each visit during treatment.

### **c) Technique**

- The child should be relaxed while the feet are checked. To help a small child feel safe and relaxed, it is good to place them on their mother's lap, while the examiner is seated in front.

### **d) Scores**

#### **Hind Foot Contracture Score (HFCS): 0-3**

1. Posterior Crease (PC)
2. Empty Heel (EH)
3. Rigid Equinus (RE)

#### **Mid Foot Contracture Score (MFCS): 0-3**

4. Medial Crease (MC)
5. Lateral part of the Head of the Talus (LHT)
6. Curvature of Lateral Border of foot (CLB)

#### **Total Score (TS): 0-6 (6=most severe)**

# PIRANI SCORING SIGNS

## 1. Posterior Crease of the ankle (PC)

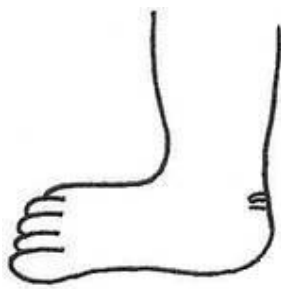The PC is a measure of the posterior contracture.

Hold the foot in a gently corrected position. Examine the back of the heel.

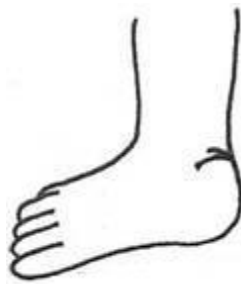**Score 0:** When multiple fine creases are visible, that do not change the contour of the heel. These creases allow the skin to adjust and stretch as the ankle dorsiflexes.

**Score 0.5:** When one or two deep creases are visible, that do not appreciably change the contour of the heel.

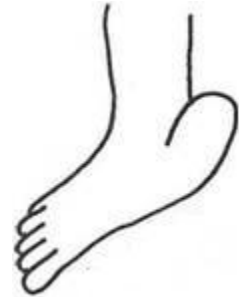**Score 1:** When one or two deep creases are visible that appreciably change the contour of the heel.



0



0.5



1

## 2. Empty Heel (EH)

The EH is a measure of the posterior contracture.

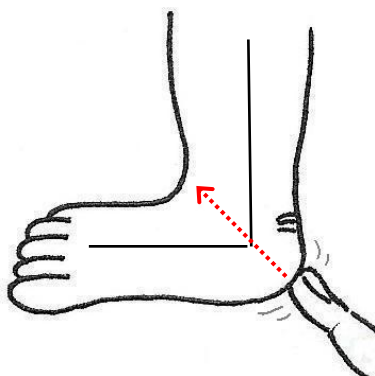
If the Talus is fully plantar flexed, the Calcaneus is also in Equinus so that the posterior aspect of the Calcaneus is drawn up and out of the heel pad. As the Plantar flexion of the Talus corrects, the Calcaneus fills the heel pad.

Hold the foot in a gently corrected position. Place the examining finger on the corner of the heel and bisect the angle between the sole of the foot and the back of the calf. Apply gentle pressure with the finger.

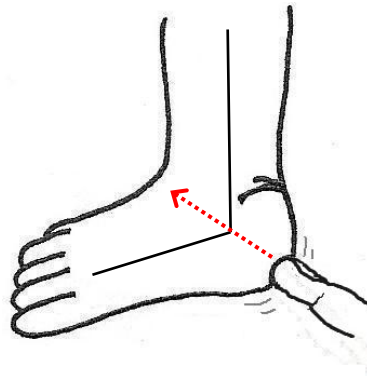
**Score 0:** The Calcaneus is immediately palpable (comparable with the feeling of gentle pressure on the temple).

**Score 0.5:** The heel pad feels soft, but the Calcaneus is palpable deep within the heel pad (comparable with the feeling of gentle pressure on the tip of the nose).

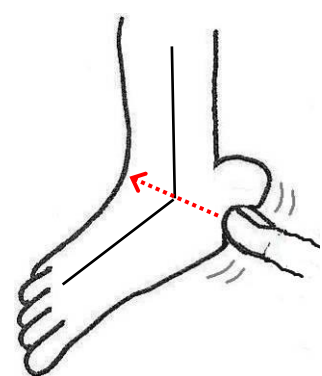
**Score 1:** The heel pad feels empty. No bony prominences can be felt (comparable with the feeling of gentle pressure on the ball of thumb).



0



0.5



1

### **3. Rigid Equinus (RE)**

The RE is a measure of the posterior contracture.

Hold the knee in full Extension and supinate the foot slightly. Then gently dorsiflex the foot as much as possible. View the leg and foot from the lateral side and measure the movement from the neutral position (0°- line).

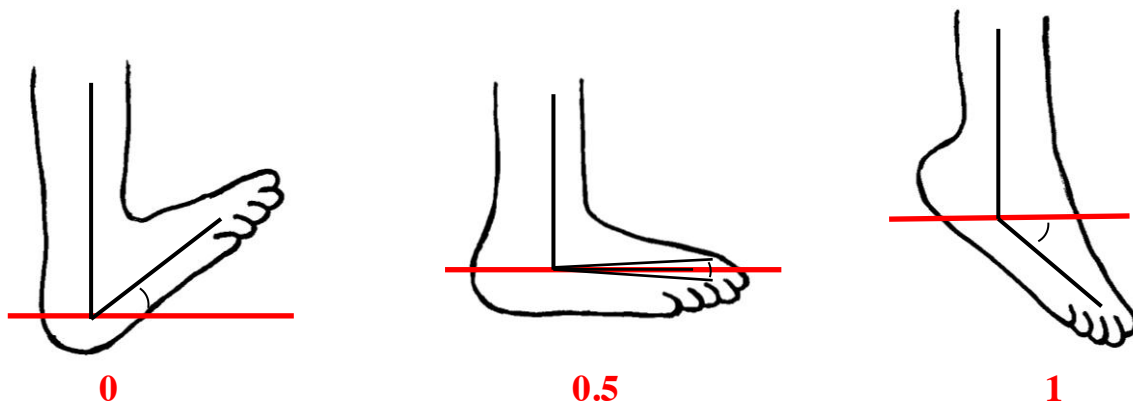
**Score 0:** Clear Dorsiflexion - more than about 5° Dorsiflexion.

**Score 0.5:** Around neutral position can be achieved.

Range: about 5° Plantar flexion to 5° Dorsiflexion.

**Score 1:** Clearly no neutral position can be achieved - more than about 5° Plantar flexion.

Beside the Pirani Score it is very helpful to write down the measured angle.



### **4. Medial Crease of the sole of the foot (MC)**

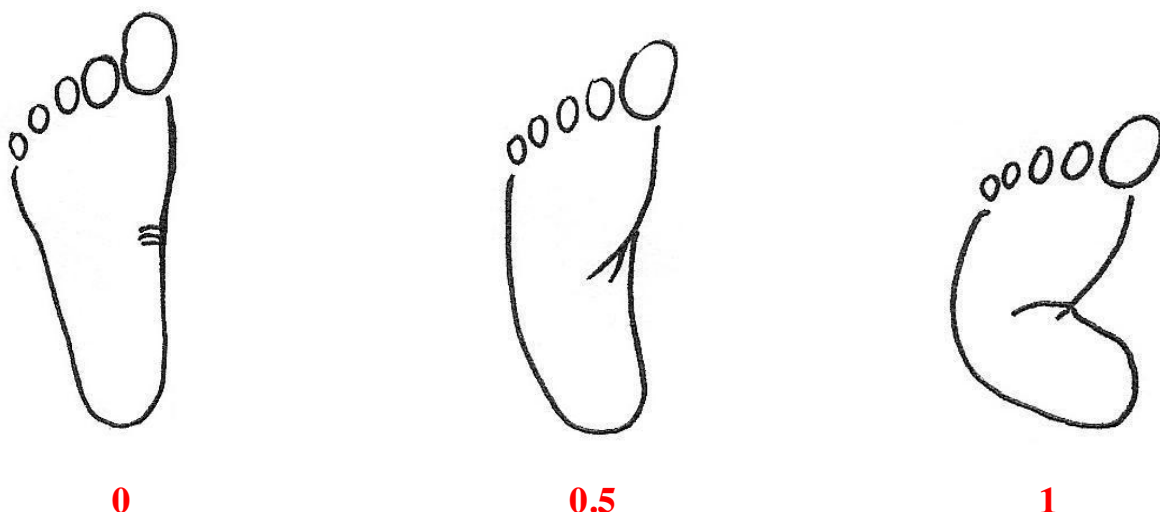
The MC is a measure of the medial contracture.

Hold the foot in a gently corrected position. Examine the medial arch of the foot.

**Score 0:** Multiple fine creases are seen which do not change the contour of the arch.

**Score 0.5:** One or two deep creases are seen which don't appreciably change the contour of the arch.

**Score 1:** One or two deep creases are seen which appreciably change the contour of the arch.



## **5. Lateral part of the Head of the Talus (LHT)**

The LHT is a measurement of how far the Navicular reduces onto the head of the Talus. In the Congenital Clubfoot the lateral part of the head of the Talus is uncovered. As the deformity corrects because of the treatment, the Navicular reduces onto the head of the Talus and covers it.

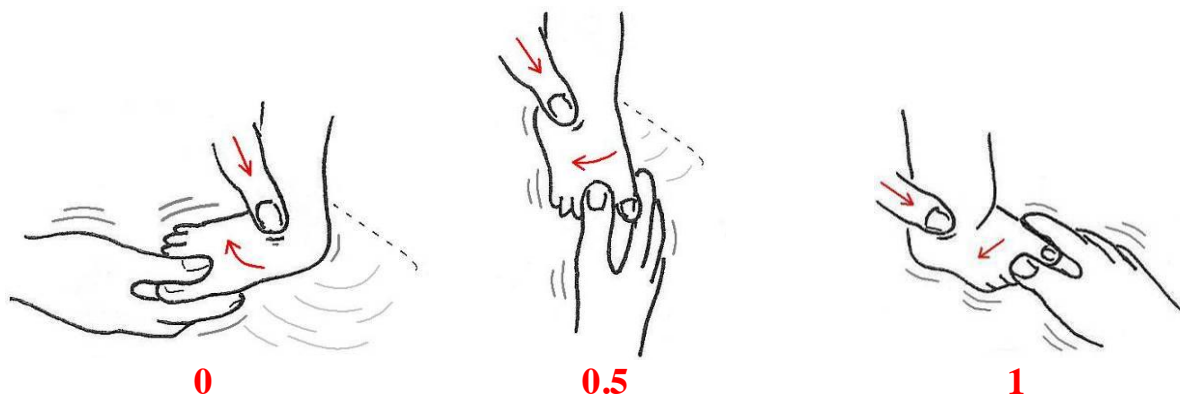Hold the foot in a deformed position. Palpate the lateral part of the head of the Talus with the pulp of the thumb. Abduct the foot with the other hand gently. Note if the Navicular reduces onto the head of the Talus.

**Score 0:** Loss of the ability to palpate the lateral edge of the head of the Talus (because of the complete reduction of the Navicular onto the head of the Talus).

**Score 0.5:** Reduction of the ability to palpate the lateral edge of the head of the Talus (because of partial reduction of the Navicular onto the head of the Talus).

**Score 1:** Still easily palpable head of the Talus even with the forefoot in as much correction as is allowed by the deformity (because of fixed medial subluxation of the Navicular).

Beside the Pirani Score it is very helpful to write down the measured angle of Abduction.



## **6. Curvature of the Lateral Border of the foot (CLB)**

The CLB is a measure of the medial contracture.

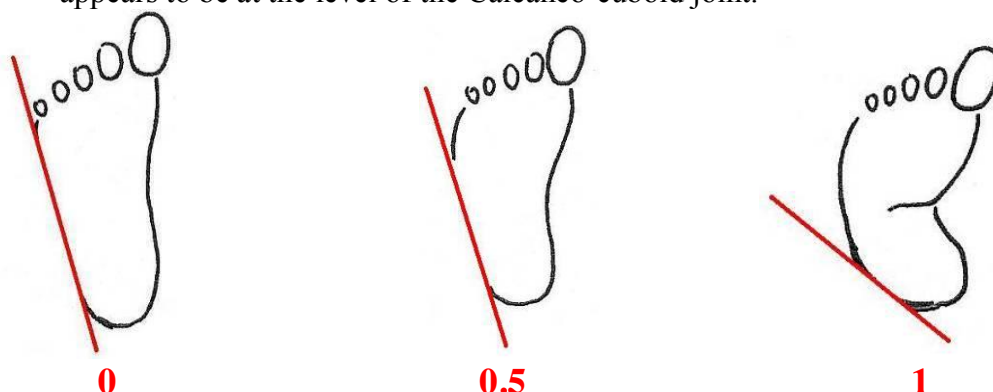
The amount of curvature can indicate the amount of medial contracture.

Examine the plantar surface of the foot and gauge the lateral border of the foot by placing a straight edge (pencil) along the lateral border of the Calcaneus.

**Score 0:** The lateral border of the foot is straight from the heel to head of the Metatarsal V.

**Score 0.5:** The lateral border of the foot is mildly curved. The curvature appears to be in the distal part of the foot in the area of the Metatarsals.

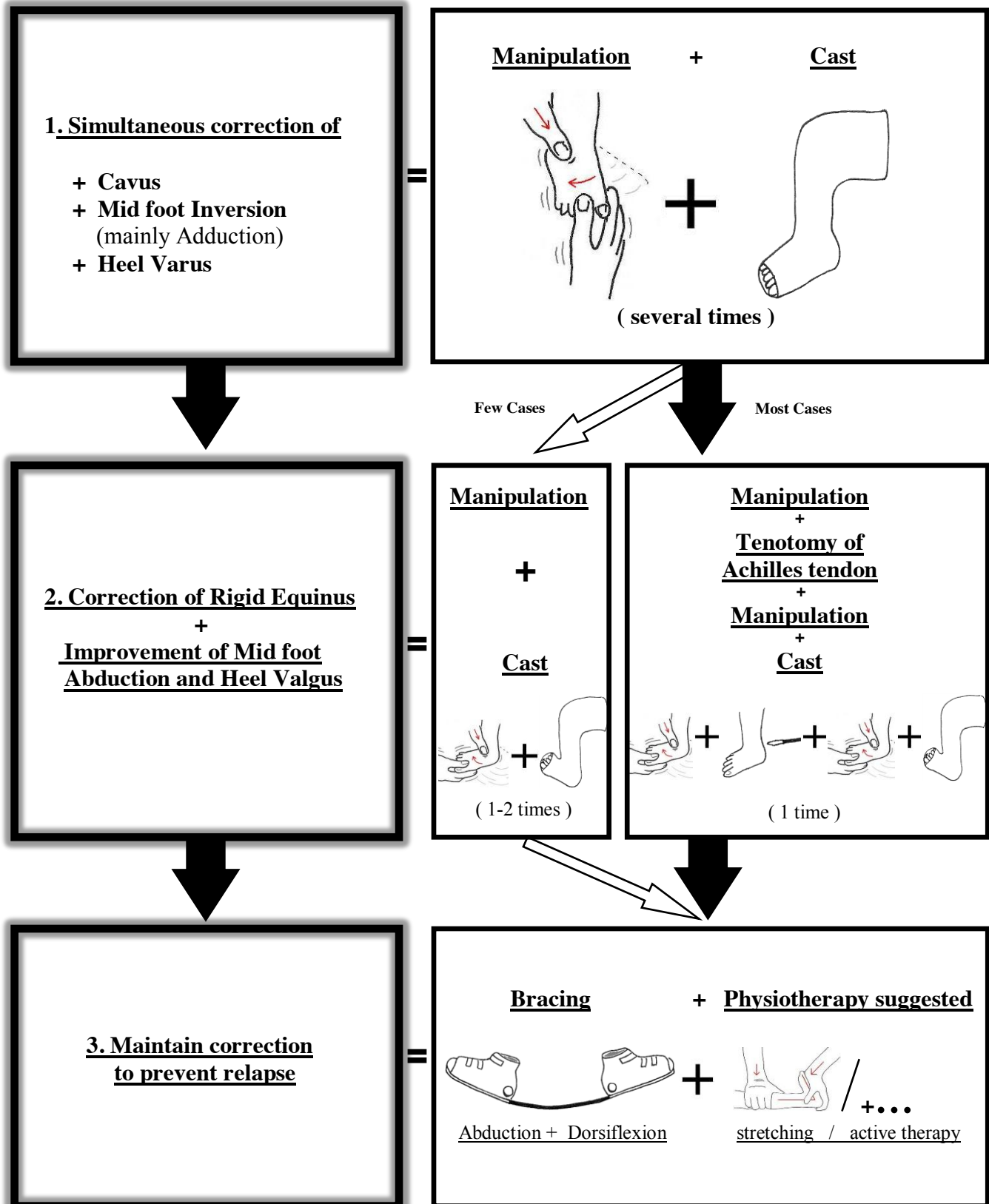
**Score 1:** A pronounced curvature of the lateral border of the foot is seen. The curvature appears to be at the level of the Calcaneo-cuboid joint.



# **OVERVIEW OF CLUBFOOT TREATMENT USING THE PONSETI METHOD (BASIC GUIDELINE)**

(Not Atypical Clubfoot or associated defect)

Gradual correction of the deformity is followed by maintaining the correction to prevent a relapse. Cavus, Mid foot Inversion, Heel Varus and the Rigid Equinus will be corrected. Displaced bones will be brought gradually into alignment. Dorsal and medial located ligaments and tendons get stretched. Joint surfaces progressively remodel.



# **EARLY CLUBFOOT TREATMENT START USING THE PONSETI METHOD (GUIDELINE)**

("Younger child" = not yet walking child – not Atypical Clubfoot or associated defect)

The treatment starts with gradual correction of the deformity: Cavus, Mid foot Inversion, Heel Varus and the Rigid Equinus need to be corrected. The tenotomy of the Achilles tendon is strongly suggested in most cases to correct the Equinus. After full correction a relapse needs to be prevented. This is done by bracing and I suggest physiotherapy as well.

## **1. Simultaneous correction of**

- + **Cavus**
- + **Mid foot Inversion**  
(mainly Adduction)
- + **Heel Varus**

### \* Result to aim for:

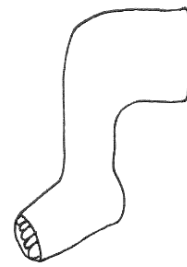
- No Cavus
- Alignment: Forefoot/Hind foot
- 50° (- 60°) Abduction  
(Talus head fully covered when abducting)
- Heel in neutral position for sure

## **Manipulation**



- 30-40 sec for 2-3 times  
= about 2 min per foot

## **Cast**



- Knee flexion: 90°
- Casts change: 5-7 days
- Cast number: 4-6

Few Cases

Most Cases

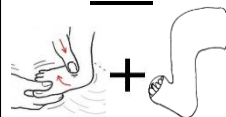
## **2. Correction of Rigid Equinus**

### **Improvement of Mid foot Abduction and Heel Valgus**

### \* Result to aim for:

- 15°-30° Dorsiflexion
- 60°-70° Abduction (Hyper abduction)
- Slight Heel Valgus

## **Manipulation**

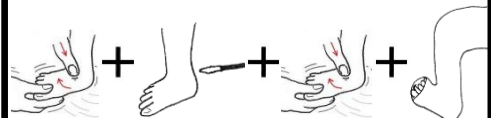


- Manipulation:  
30-40 s for 2-3 times

- Cast:  
Knee flexion: 90°  
Casts change: 5-7 days  
Casts number: 1-2

## **Manipulation**

### **+ Tenotomy of Achilles tendon + Manipulation + Cast**



- Manipulation:  
- 30-40 sec for 2-3 times
- Cast:  
- Knee flexion: 90°  
- Last cast: 3 weeks  
- Cast number: 1

## **3. Maintain correction to prevent relapse**

### \* Result to aim for:

- + Functional, flexible, active,  
normal looking foot

Focus on:

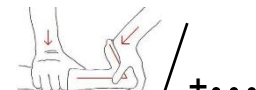- 15°-30° Dorsiflexion
- 60°-70° Abduction
- Slight Heel Valgus

## **Bracing**



70° Abd + 10°-20° Dorsiflex

## **+ Physiotherapy suggested**



Stretching / Active therapy

### **\* Children start bracing under 9 months of age**

- |                         |                      |                |
|-------------------------|----------------------|----------------|
| 1. Fulltime             | = 23 hours a day:    | 3 months       |
| 2. Monthly reduced time | = 16-22 hours a day: | 3 months       |
| 3. Night and nap time   | = 14-16 hours a day: | several months |
| 4. Night time           | = 12-14 hours a day: | till age 4-5   |

### **\* Children start bracing above 9 months of age**

- |                 |                      |              |
|-----------------|----------------------|--------------|
| 1. Most time    | = 18-20 hours a day: | 2 months     |
| 2. Reduced time | = 16 hours a day:    | 3-4 months   |
| 3. Night time   | = 12-14 hours a day: | till age 4-5 |

# **LATER CLUBFOOT TREATMENT START USING THE PONSETI METHOD (GUIDELINE)**

("Older child" = already walking child – not Atypical Clubfoot or associated defect)

Depending on the child's age and severity of the Clubfoot, gradual correction is done as much as possible. Cavus, Mid foot Inversion, Heel Varus and the Rigid Equinus need to be addressed for correction. Especially in older children I strongly suggest physiotherapy to accompany the following bracing phase. Some older children may require further surgery.

## **1. Simultaneous correction of**

- + Cavus**
- + Mid foot Inversion**  
(mainly Adduction)
- + Heel Varus**

### **\* Result to aim for:**

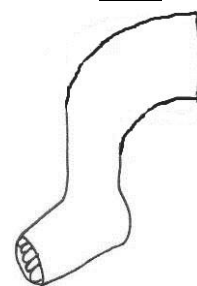
- No Cavus
- Alignment: Forefoot/Hind foot
- 30°- 50° Abduction (Talus head fully or mostly covered when abducting)
- Heel in neutral position for sure

## **Manipulation**



- 1-2 min for 4-5 times  
= 5-10 min per foot

## **+ Cast**



- Knee flexion: 70°
- Casts change: 7-10 (14) days
- Cast number: 6-12

=

Few Cases

Most Cases

## **2. Correction of Rigid Equinus**

+

### **Improvement of Mid foot Abduction and Heel Valgus**

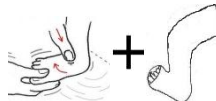### **\* Result to aim for:**

- 10° – 20° Dorsiflexion
- 30° – 60° Abduction
- Slight Heel Valgus

## **Manipulation**

+

### **Cast**



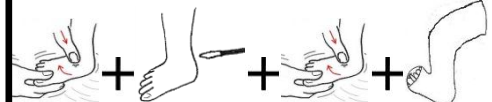
- Manipulation:**  
1-2 min for 4-5 times

- Cast:**  
Knee flexion: 70°  
Casts change: 7-10(14) days  
Casts number: 1-2

=

## **Manipulation**

### **+ Tenotomy of Achilles tendon + Manipulation + Cast**



- Manipulation:**  
- 1-2 min for 4-5 times
- Cast:**  
- Knee flexion: 70°  
- Last cast: 4 weeks  
- Cast number: 1

## **3a) Maintain correction to prevent relapse**

## **3b) Get foot used to correction and support remodelling of bones (mainly in children above 4 years)**

### **\* Result to aim for:**

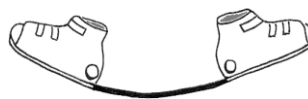- + Functional, flexible, active,  
normal looking foot

Focus on:

- 10°-20° Dorsiflexion
- 30°-60° Abduction
- Slight Heel Valgus in standing

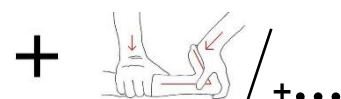=

## **Bracing**



40°-60° Abd + 10°-20° Dorsiflex

## **+ Physiotherapy suggested!!**



Stretching / Active therapy!!

### **\*) Children start bracing under 4 years of age**

- 1. Most time = 16-18 hours a day: 3-4 months
- 2. Night time = 12-14 hours a day: till age 5

### **\*) Children start bracing above 4 years of age**

- 1. Night time = 12-14 hours a day: for 1 year

# MANIPULATION

The technique of the manipulation is based on the understanding of the described coupling of movements (= the foot follows the track).

In practice this means to correct the hind foot we need to manipulate the mid foot. The initiator for the correction of the whole foot is the **Abduction** of the mid foot.

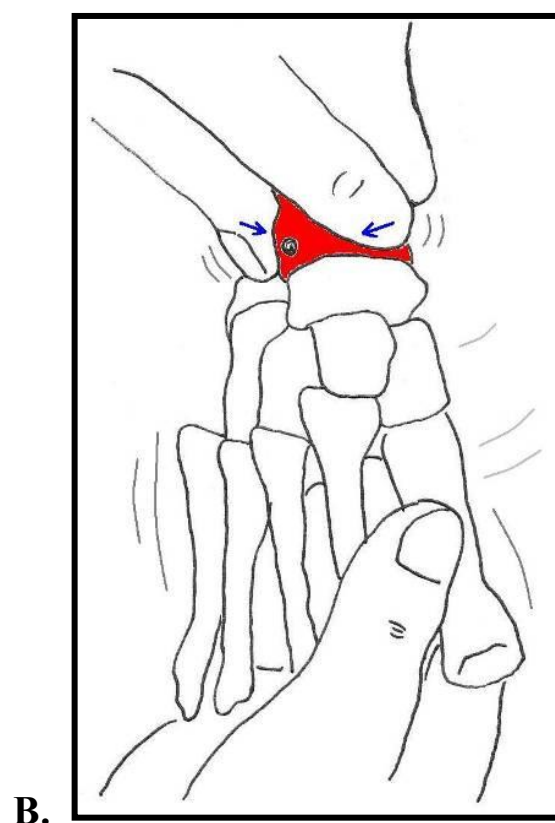
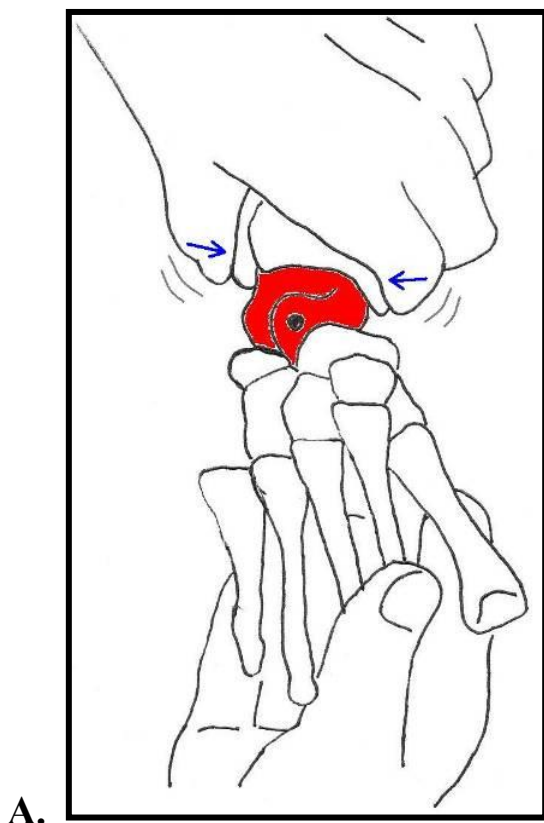
## 1. Precise identification of the head of the Talus and Talo-calcaneo-navicular joint

It is very important to localize the head of the Talus very well to prevent a wrong manipulation and failure of the treatment.

- A.** 1) Grasp the (right) forefoot with the (right) hand.  
2) With (left) thumb and index finger feel the Malleoli from the front.

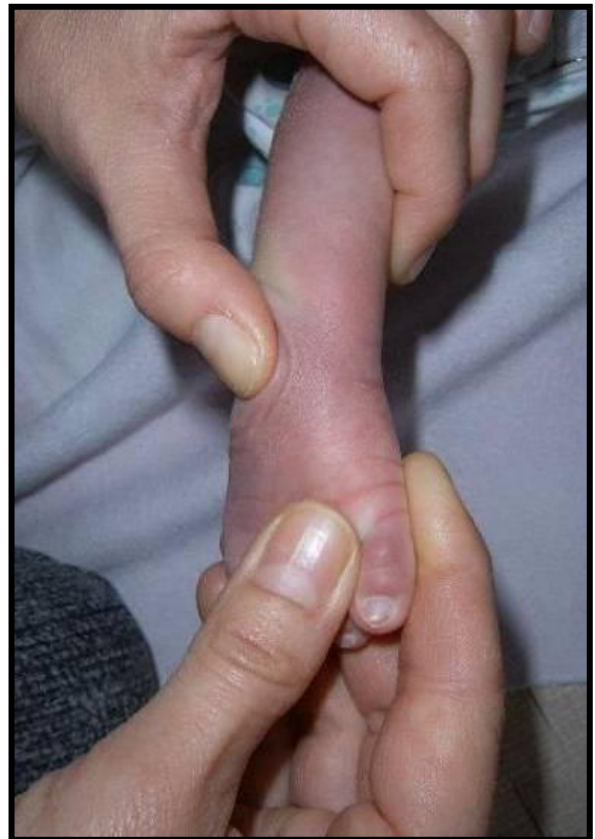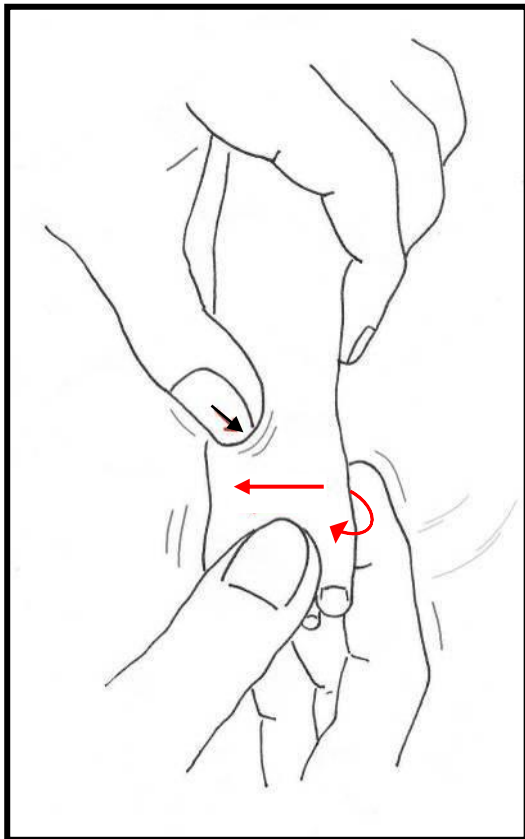
**then**

- B.** 1) Move the (left) thumb and index finger forward to clasp the head of the Talus.  
In this position:  
a) Feel the Navicular with the tip of your index finger.  
b) Feel the anterior tuberosity of Calcaneus with the tip of your thumb.  
2) Abduct the forefoot slowly and feel the motion in the Talo-calcaneo-navicular joint:  
a) Navicular moves in front of the head of the Talus.  
b) Anterior tuberosity of the Calcaneus moves laterally under the head of the Talus.



## **2. Manipulation technique**

- 1. Stabilize the Talus** by placing the thumb over the head of the Talus.  
This provides a pivot point around which the foot is abducted.
- 2. Manipulate the foot with Supination followed by Abduction** with the other hand. This should not cause any discomfort to the child.  
In the beginning much Supination is required, but Supination will automatically decrease with more achieved Abduction.
- 3. Hold the correction with gentle pressure, then release and repeat.** Use the following guidelines for children without other defect associated:
  - a) “Younger child” (= not walked at treatment start):
    - Hold the correction for 30-40 seconds, then release and repeat 1-2 times.  
It will take around 2 minutes per Clubfoot.
  - b) “Older child” (= already walked at treatment start):
    - Hold the correction for 1-2 minutes, then release and repeat 3-4 times.  
It will take 5-10 minutes per Clubfoot.



**Never pronate!!!**

**Never touch the heel!!!**

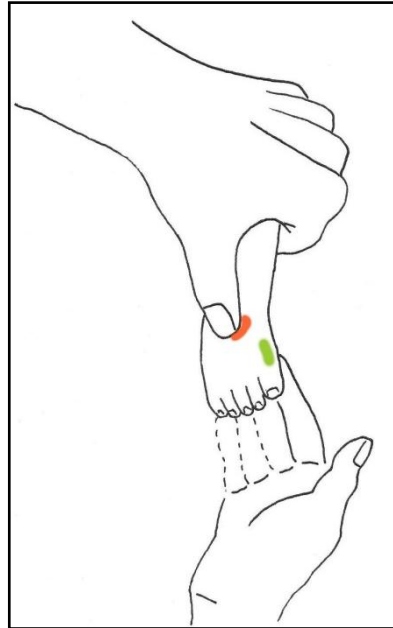
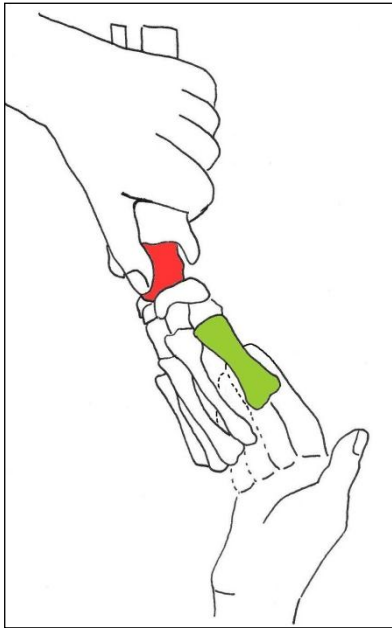
**Never use mere force!!!**

The manipulation can be done on the mother's lap and should not cause pain for the child. It should be done gently, so that the ligaments get stretched according to their natural capacity.

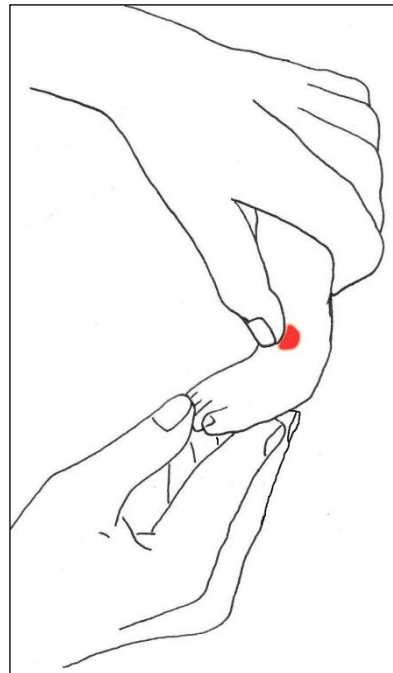
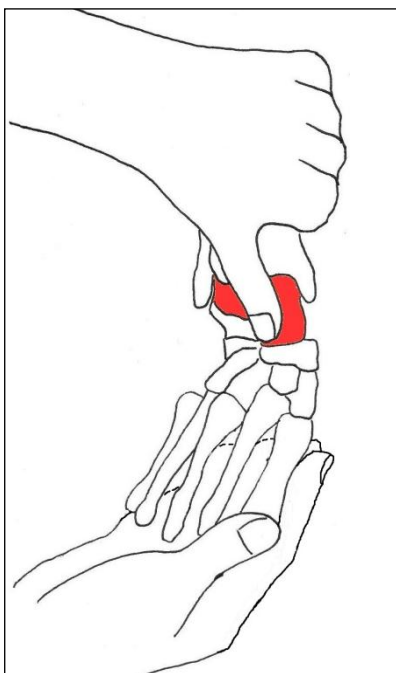
# HANDPOSITIONS FOR MANIPULATION

## A) Two-hands-position 1

- Step 1:** \* With the hand coming from up front:  
Stabilize the Talus by placing the thumb on the head of the Talus.
- \* With the other hand:  
Raise the first ray (= Metatarsal I and the Phalanges of the first toe). Do this by placing index and middle finger under the plantar-medial part of the Metatarsal I.
- Result: More Supination of the forefoot.**
- Goal: Get the forefoot in line with the mid foot in terms of Supination.**



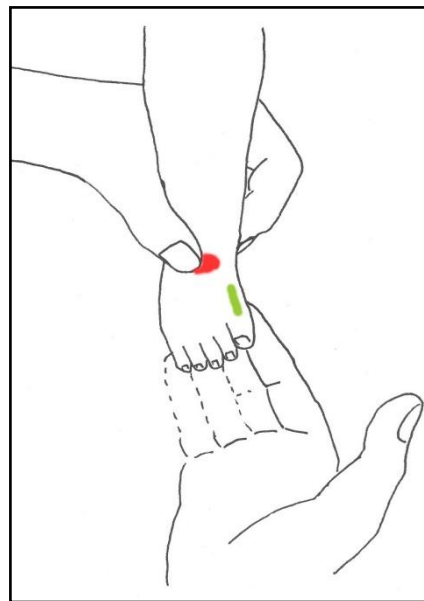
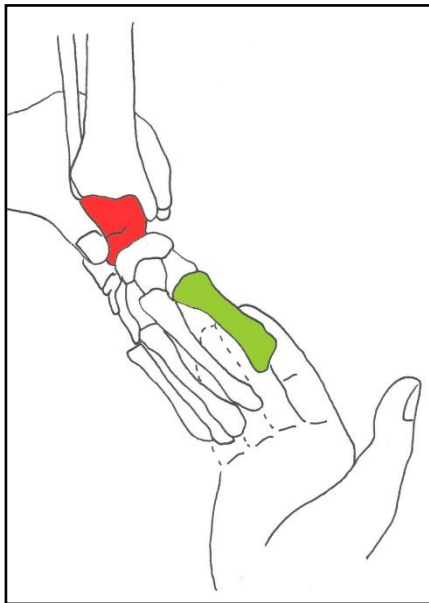
- Step 2:** Move the forefoot into Abduction and the mid foot will follow. Supination decreases with the increase of Abduction. Around 50° Abduction, no Supination needs to be kept anymore, but never move the foot actively in the direction of Pronation.
- Goal: Gradual correction of Mid foot Inversion and Heel Varus.**



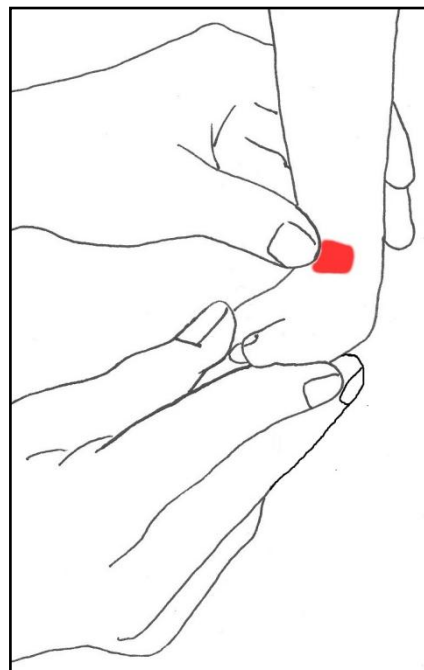
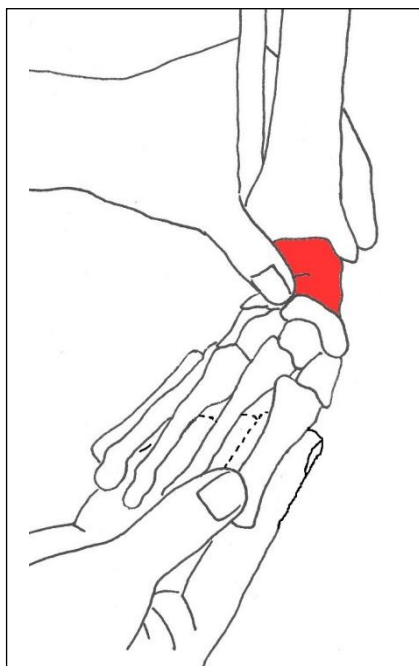
# HANDPOSITIONS FOR MANIPULATION

## B) Two-hands-position 2

- Step 1:**
- \* With the hand coming from back:  
Stabilize the Talus with placing the thumb on the head of the Talus.  
Don't touch the heel by accident!!!
  - \* With the other hand:  
Raise the first ray (= Metatarsal I and the Phalanges of the first toe). Do this by placing the index and middle finger under the plantar-medial part of the Metatarsal I.
- Result: More Supination of the forefoot.**  
**Goal: Get the forefoot in line with the mid foot in terms of Supination.**



- Step 2:**
- Move the forefoot into Abduction and the mid foot will follow. Supination decreases with the increase of Abduction. Around 50° Abduction, no Supination needs to be kept anymore, but never move the foot actively in the direction of Pronation.
- Goal: Gradual correction of Mid foot Inversion and Heel Varus.**



# CASTS AFTER MANIPULATIONS

The cast is applied after the manipulation and immobilizes the foot in order to stretch the tight ligaments, joint capsules and tendons.

Always use long leg casts up to the groin in order to keep the foot under the Talus in Abduction and prevent Rotation in the ankle mortise. In the “younger child” (= not walked before treatment start) cast the knees in 90° Flexion and change the cast every 5-7 days. In the “older child” (walked before treatment start) cast the knees in 70° Flexion, so that they can stand up and change the casts every 7-10 (14) days. The last cast, if tenotomy of the Achilles tendon is done, will stay for 3 weeks in the “younger child” and 4 weeks in “older child”.

While casting change hand positions to avoid long pressure over the Talus and other spots to prevent pressure sores. Always mould well at the heel, Malleoli and sole of the foot.

The main focus in the first cast is the correction of the Cavus by supinating the fore foot, but Mid foot Inversion and Heel Varus are addressed as well by gentle Abduction. When the Cavus is eliminated, Mid foot Inversion and Heel Varus have to be corrected in the following casts. Aim to achieve the neutral position of the heel for sure and in the “younger child” 50° (-60°) Abduction, in the “older child” 30° - 50° Abduction. Finally (in most cases after tenotomy of the Achilles tendon) correct the Equinus, but simultaneously improve Mid foot Abduction and Heel Valgus. The last cast should have 60° - 70° Abduction + 15° - 30° Dorsiflexion in the “younger child” and 30° - 60° Abduction and 10° - 20° Dorsiflexion in the “older child”.

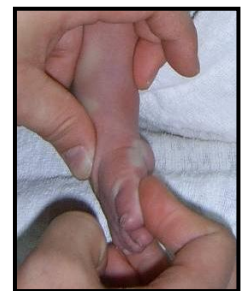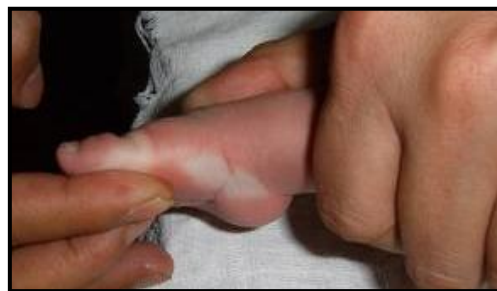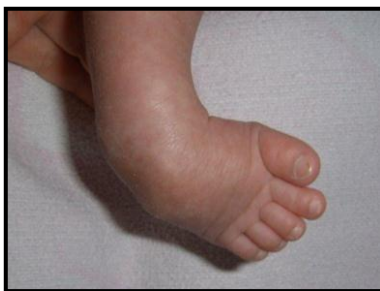Never hold the heel when casting! Never cast the foot in a pronated position! Avoid External rotation of the knee!

## 1. First cast: Correction of the Cavus (main focus)

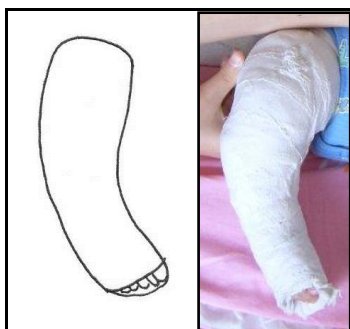### + Correction of Mid foot Inversion and Heel Varus

= Aim for the alignment of forefoot and mid foot by supinating the fore foot and some Abduction.

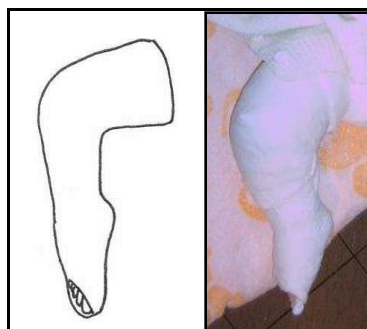
- 1. Stabilize the Talus** by placing the thumb over the lateral part of the head of the Talus.
- 2. Elevate the first ray and achieve a homogeny Supination of the forefoot in line with the mid foot. Then abduct the foot gently.**



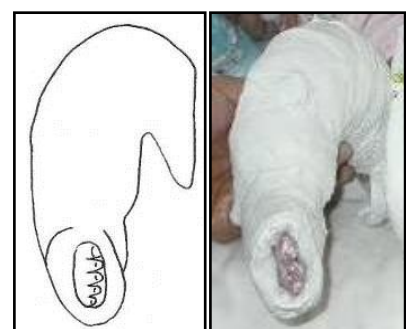- 3. Hold the corrected position while an assistant applies padding and plaster. Change hand positions and mould well at the heel, Malleoli and sole of the foot.** In small babies correction of the Cavus usually occurs with the first cast. A severe Cavus in a stiff foot will need 2 or 3 cast changes for correction.



Front View



Medial View



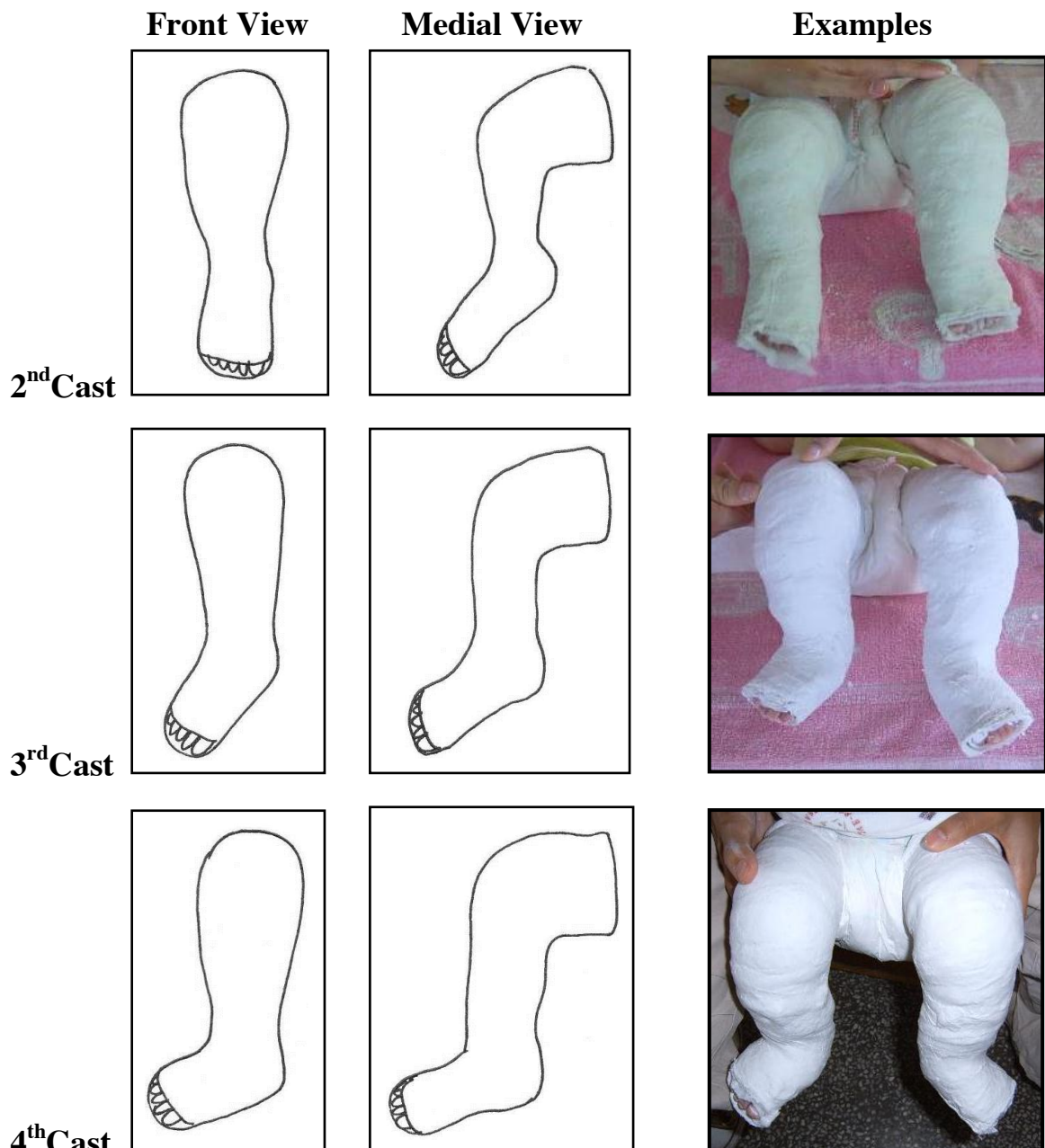Caudal View

## **2. Following casts: Correction of Mid foot Inversion and Heel Varus** **+ Continue Correction of Cavus (if needed)**

In each cast aim for more Abduction while Supination automatically decreases. In a severe Clubfoot with still strong Cavus after the first cast, make the correction of the Cavus your priority.

In the “younger child” (= not walked before treatment) aim for 50° (- 60°) Abduction and the heel in neutral position for sure. In the “older child” (= already walked before treatment) aim for 30°-50° Abduction and the heel in neutral position for sure as well.

- 1. Stabilize the Talus** by placing the thumb over the lateral part of the head of the Talus.
- 2. Hold the foot in Abduction with the appropriate degree of Supination** while applying the cast. Remember that Supination decreases with the increase of Abduction. At about 50° Abduction, no Supination needs to be kept anymore, but never hold the foot in Pronation. The correction of the Calcaneus will be achieved because of coupling. Plaster as often as you need to get enough Abduction.
- 3. Hold the corrected position while an assistant applies padding and plaster. Mould well by changing hand positions.**



### **3. Last cast(s): Correction of Rigid Equinus in the ankle**

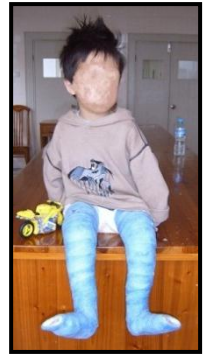(after Achilles tendon tenotomy in most cases)

#### **+ Improvement of Mid foot Abduction and Heel Valgus**

However with performed tenotomy of the Achilles tendon right before (most cases) or without (less cases), focus on the maximal possible Dorsiflexion and Abduction in the last cast.

The position to aim for is 15°- 30° Dorsiflexion with 60°- 70° Abduction in the “younger child” and 10°- 20° Dorsiflexion with 30°- 60° Abduction in the “older child”. In Atypical Clubfoot or Clubfoot associated with other defects, less Abduction and Dorsiflexion may be possible (see [Appendices 5+6](#)). In general only one cast is needed after performed tenotomy, but in difficult cases (e.g.: Atypical Clubfoot/syndromes/teenager) with severe Equinus you may decide for a second cast to achieve at least neutral position to 5° Dorsiflexion. If you decide for a second cast after tenotomy, apply the second cast after 4-5 days; but the last cast after the tenotomy needs to stay prolonged for 3 weeks in the “younger child” and 4 weeks in the “older child”.

Make sure to apply pressure from behind (not forefoot) to get the Dorsiflexion in the ankle joint and to prevent a rocker bottom deformity. While casting keep the Dorsiflexion firm, because moving the foot in Plantar flexion and back to Dorsiflexion may cause pressure sores in the front by plaster pressing in.

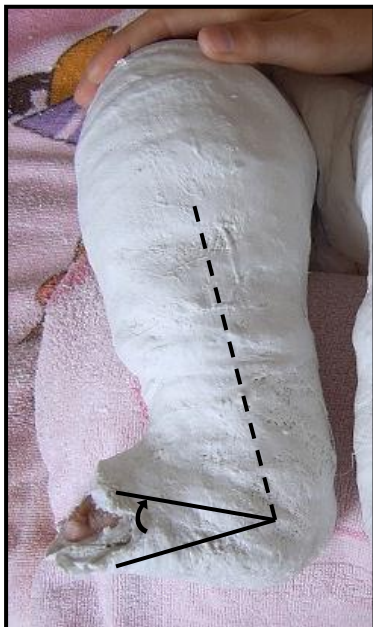

**1. Stabilize the Talus** by placing the thumb over the lateral part of the head of the Talus.


**2. Move the foot in maximal possible Abduction without any Pronation and then into**

**Dorsiflexion in the ankle with the lower hand.** By abducting, the Navicular should now fully cover the head of the Talus, so that the thumb will lose the ability to palpate the lateral head of the Talus. Therefore remove your thumb which stabilized the Talus in the beginning and then move the foot in Dorsiflexion. To achieve a better Dorsiflexion, grab the heel, pull it down and give gentle pressure under the entire sole into Dorsiflexion. Never use mere force or give pressure in the forefoot area trying to achieve more Dorsiflexion – it can cause a rocker bottom deformity. After maximal Abduction and Dorsiflexion has been achieved, move the lower hand to the toes of the child.

**3. Hold the corrected position while an assistant applies padding and plaster. Change hand positions and mould well at the heel, Malleoli and sole of the foot.**



**Dorsiflexion**



**Abduction**

After the cast is removed, the foot may appear overcorrected, but “Hyper abduction” of 70° in babies is a helpful measure to prevent a recurrence.

# HANDPOSITIONS FOR CASTING

## A) Two-hands-position 1

### **- Beginning of casting -**

**Step 1:** \* With the hand coming from up front:

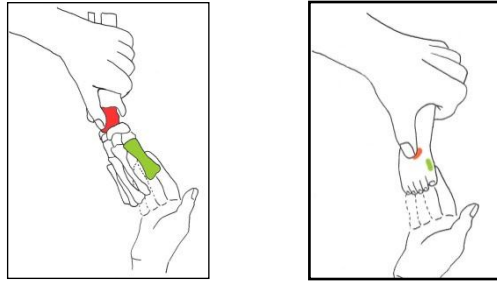
Stabilize the Talus by placing the thumb on the head of the Talus.

\* With the other hand:

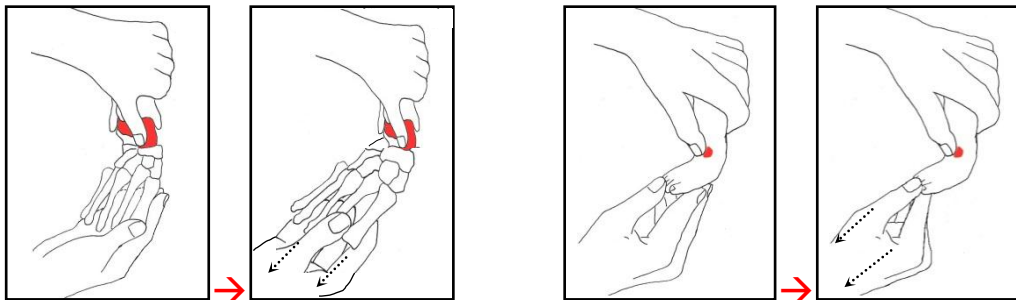
Raise the first ray (= Metatarsal I and the Phalanges of the first toe). Do this by placing the index and middle finger under the plantar-medial part of the Metatarsal I.

**Result: More Supination of the forefoot.**

**Goal: Get the forefoot in line with the mid foot in terms of Supination.**

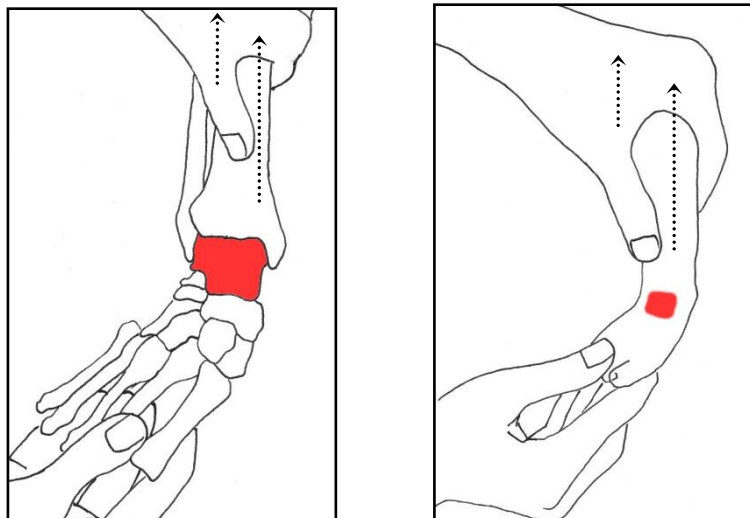


**Step 2+3:** Move the forefoot into Abduction and the mid foot will follow. Supination decreases with the increase of Abduction. Around 50° Abduction, no Supination needs to be kept anymore, but never move the foot actively in the direction of Pronation. Then move the lower hand down to the toes and pull them while the plaster is applied at the forefoot up to the mid foot.



Difference for the last cast (= maximal Abduction and Dorsiflexion) see description page 27.

**Step 4:** While the plaster is applied by the assistant at the hind foot and ankle area, your upper hand has to move up to give room for the plaster. While you move the hand up, keep the lower leg stable avoiding an External rotation in the knee! At the same time keep the corrected position of the foot with your lower hand.



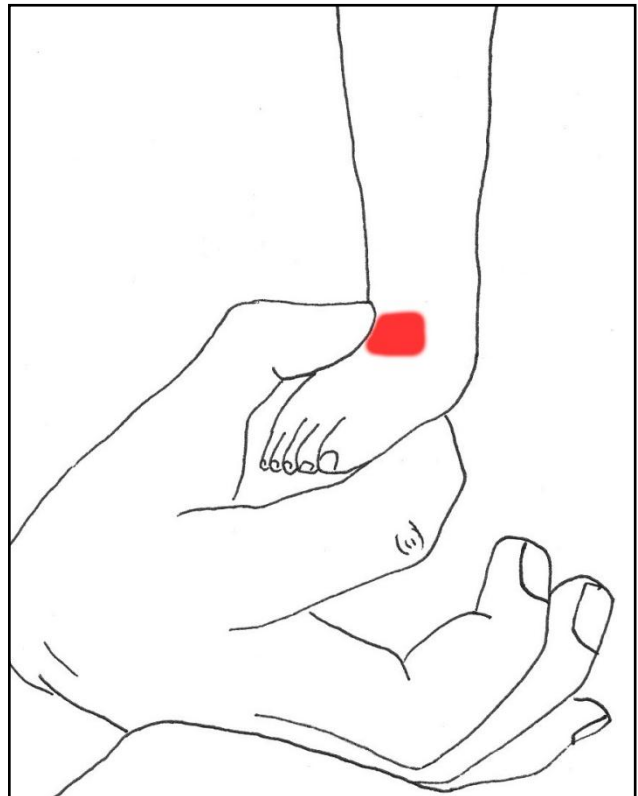
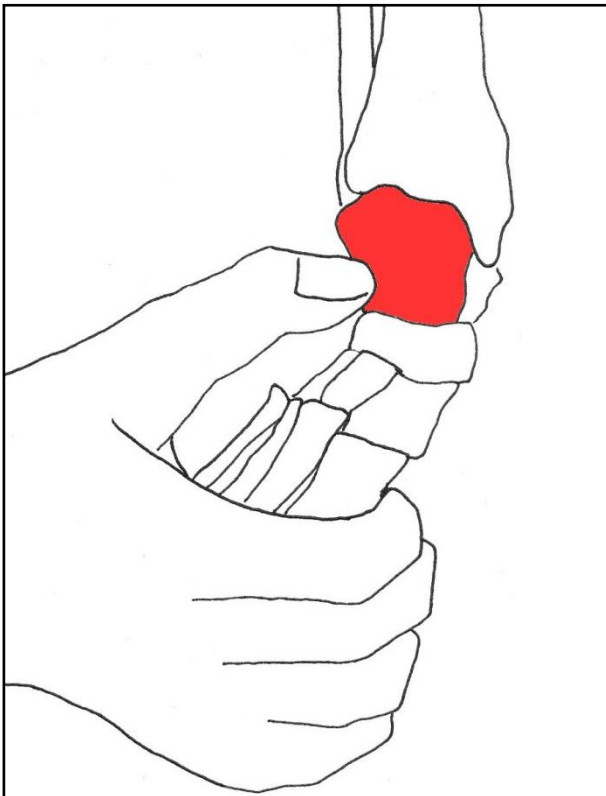
# **HANDPOSITIONS FOR CASTING**

## **B) One-hand-position 1**

**- Not in the last cast, which is in maximal Abduction and Dorsiflexion –**

**Change from the "Two-hands-position 1" to this "One-hand-position 1" right after the plaster has been applied at the hind foot and ankle area. At the transition keep the foot in the corrected position.**

- \* With one hand hold the foot in Abduction with the appropriate degree of Supination by:
  - placing the thumb on the head of the Talus for stabilizing the Talus.
  - placing the index finger at the plantar-medial part of the Metatarsal I.
- \* With the free hand mould the cast; especially above the Calcaneus, plantar-dorsal of both Malleoli and at the sole of the foot. Don't mould above or on the Malleoli to prevent a pressure sore.
- \* Remember that Supination decreases with the increase of Abduction. Around 50° Abduction, no Supination needs to be kept anymore, but never move the foot actively in the direction of Pronation.



**Change between this "One-hand-position 1" and the "One-hand-position 2" for moulding well till the plaster is not soft anymore. To prevent a pressure sore above the Talus the stabilizing thumb must not put pressure on the same spot all the time, but should always move a little bit over the head of the Talus.**

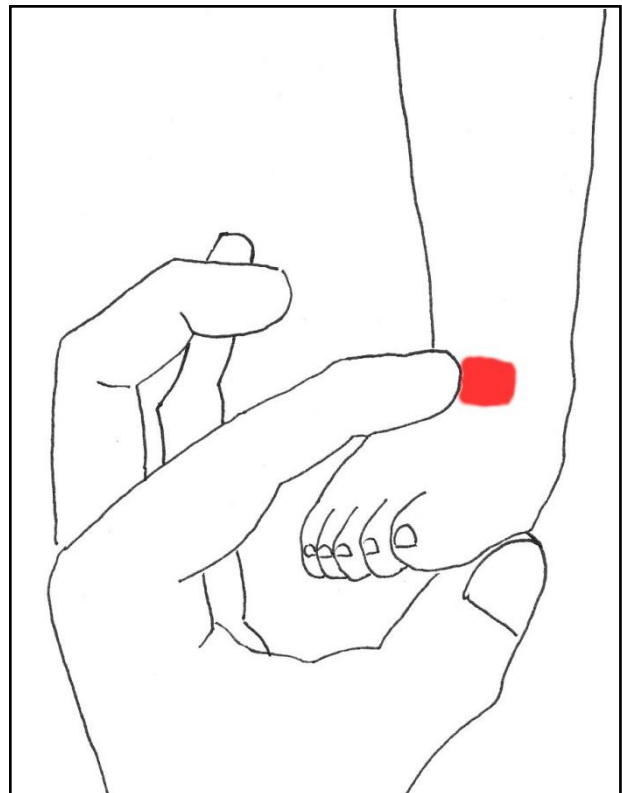
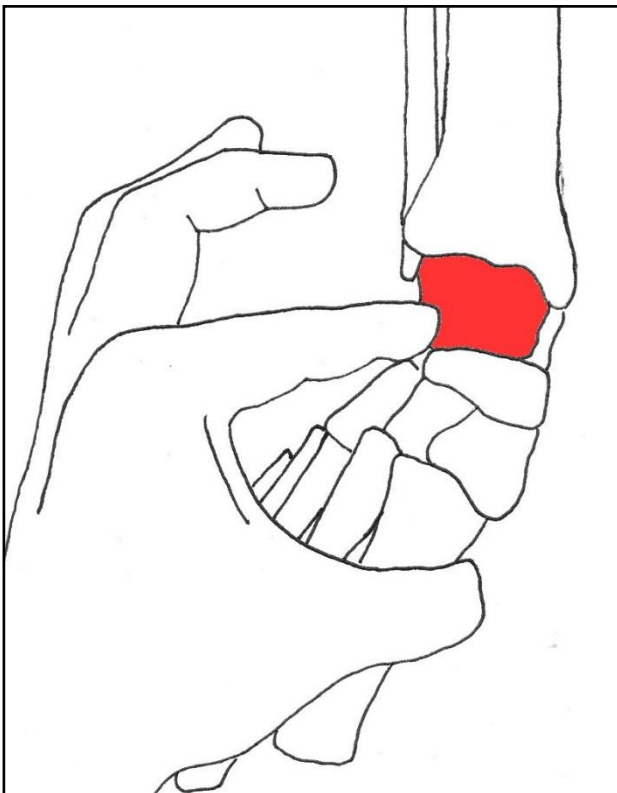
# **HANDPOSITIONS FOR CASTING**

## **C) One-hand-position 2**

**- Not in the last cast, which is in maximal Abduction and Dorsiflexion –**

**Change from the "One-hand-position 1" to this "One-hand-position 2" after the plaster has been applied at the hind foot and ankle area. At the transition keep the foot in the corrected position.**

- \* With one hand hold the foot in Abduction with the appropriate degree of Supination by:
  - placing the index finger on the head of the Talus for stabilizing the Talus.
  - placing the thumb at the plantar-medial part of the Metatarsal I.
- \* With the free hand mould the cast; especially above the Calcaneus, plantar-dorsal of both Malleoli and at the sole of the foot. Don't mould above or on the Malleoli to prevent a pressure sore.
- \* Remember that Supination decreases with the increase of Abduction. Around 50° Abduction, no Supination needs to be kept anymore, but never move the foot actively in the direction of Pronation.



**Change between this "One-hand-position 2" and the "One-hand-position 1" for moulding well till the plaster is not soft anymore. To prevent a pressure sore above the Talus the stabilizing finger must not put pressure on the same spot all the time, but should always move a little bit over the head of the Talus.**

# **CASTS REMOVAL**

**The removal of the casts needs to be done in the clinic just before the next step of the treatment.** Do not allow the parents to remove the casts at home, because correction can be lost if the child's feet are out of the corrected position for an extended time.

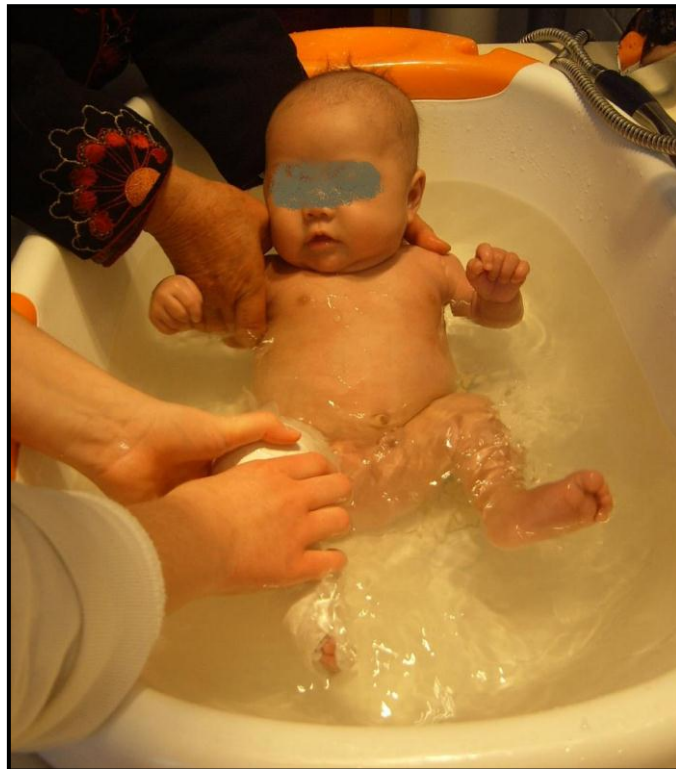Find the end of the plaster role which makes it easier to unwrap the softened plaster. Always leave a lump at the end of every plaster role, when the casts are applied so that the end is easy to locate.

## **1. Soak the casts**

- a) Put the child into a warm bath for some minutes to soften the cast. In addition press the cast carefully with your hands. This should be done at the clinic after you checked the condition of the casts.
- b) If the weather is very cold put only the plastered legs in warm water or wrap them in damp towels and press the cast carefully with your hands.

## **2. Remove the casts**

- a) Unwrap the softened plaster roles while the child is still in the bath tub or sitting on the mother's lap. This is a safe method, but takes extra time.
- b) When using a plaster knife, cut obliquely to avoid cutting the skin. First remove the cast above the knee and then below the knee.



**Avoid using a plaster saw** because it frightens the child and can injure sensitive skin.

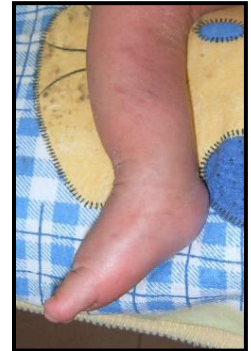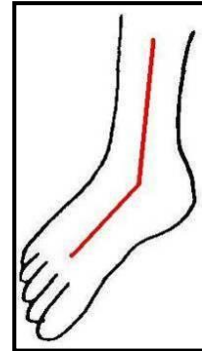
Allow the parents to give the child a quick bath after the plaster has been removed.

# **PERCUTANEOUS TENOTOMY**

## **OF THE ACHILLES TENDON**

### **1. Reason: Correction of the rigid ankle foot Equinus.**

After Cavus, Mid foot Inversion and Heel Varus are corrected, the Equinus needs to be addressed for correction. In most cases the Achilles tendon is quite tight and holds the posterior part of the Calcaneus up. By cutting the tendon this strong force keeping the Calcaneus in strong Equinus will be eliminated.



### **2. Which child requires a tenotomy:**

It is suggested to perform a tenotomy of the Achilles tendon in most cases and even in older children. The attempt to correct a Rigid Equinus gradually by casting runs the risk of too much pressure on the Talus with the result of flattening the Talus.

Some milder cases, meaning mild limitation of Dorsiflexion, don't require a tenotomy. If 20° Dorsiflexion can be achieved easily after the casts corrected the other parts of the deformity, a tenotomy is not necessary.

### **3. Result:**

After performed tenotomy an improvement of 10° Dorsiflexion or more should be achieved.

### **4. Guideline for timing:**

- + The Pirani Severity Scoring Method indicates when sufficient correction has been obtained:
  - \* Mid foot Contracture Score under 1
  - \* Hind foot Contracture Score over 1
  - \* LHT = 0 (in older children or children with associated defects, the Talus head may not be fully covered)
- + Heel in neutral position for sure (no Heel Varus!)  
Never perform a tenotomy, if the heel is still in Varus, because not enough correction has been achieved.
- + Exception: In a child with Atypical Clubfoot or Clubfoot associated with another defect slipping out of the cast regularly, a tenotomy can be performed earlier.

### **5. Procedure:**

It is a minor surgical procedure, so does not require the operating theatre. It should be done by an orthopaedic surgeon and an assistant.

#### Equipment:

- Some antiseptic and equipment to apply the antiseptic
- Gloves
- Local anaesthetic in a small syringe with small gauge needle (lignocaine 0.5cc)
- Scalpel blade #11(sharp) and handle
- Gauze
- For older children mild sedative to calm them.  
(You can use Lumina: 1mg per kg of the child's weight. Injection 30min before tenotomy.)

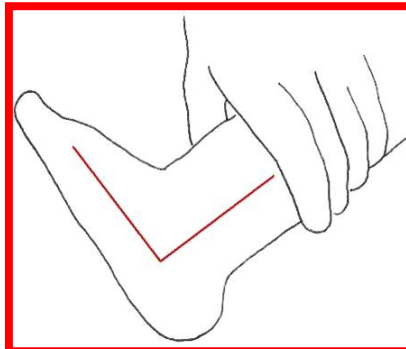
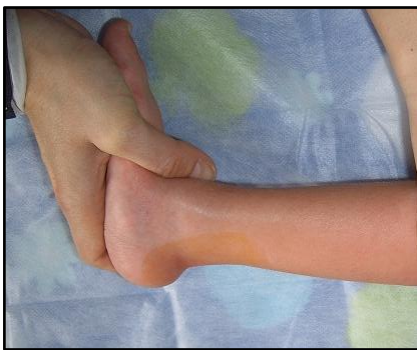#### Position of the child:

Lay the child on their back, with their legs externally rotated.

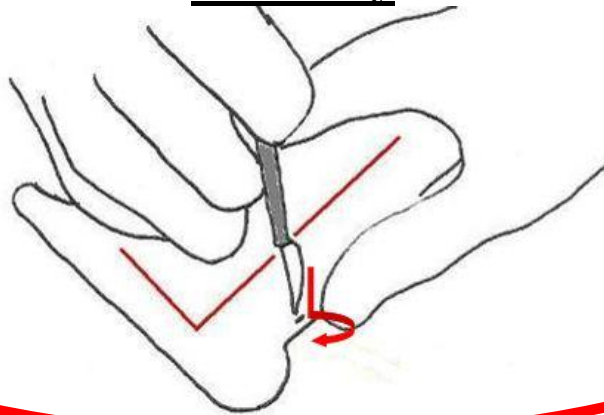
1. Skin preparation with antiseptic.
2. Infiltration of local anaesthesia near the tendon.
3. Cut the tendon completely:

The assistant needs to hold the knee straight and the ankle in Dorsiflexion, so the tendon is under stress. About 1 cm above the Calcaneus, the scalpel blade with the sharp side in proximal direction, is inserted from the medial side parallel to the Achilles tendon. The blade is to rotate gently to cut the tendon completely. Take care not to cut the skin above. A “pop” is felt and the foot immediately dorsiflex more and may become white. Place clean gauze over the incision and hold it for about 5 minutes and make sure the wound is not bleeding anymore.

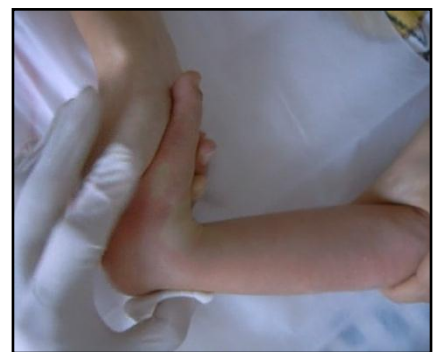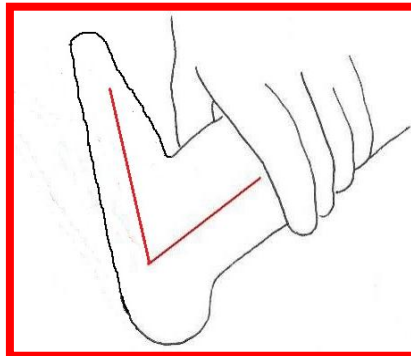
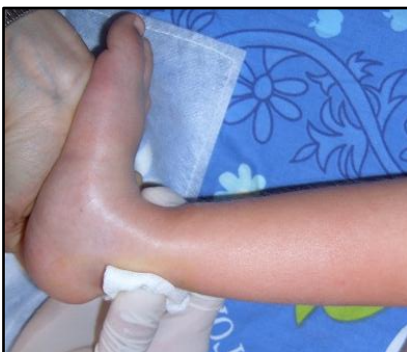#### Before Tenotomy



#### Tenotomy



#### After Tenotomy




4. Manipulate and then cast the foot in maximal Dorsiflexion and Abduction as described on page 27.

# THE BRACING

## 1. The bracing is a very important and a critical part of the Ponseti treatment

- After the clubfoot is corrected it has to be held in a corrected position for some times to prevent recurrence. The brace is not a tool for correction.
- Failure to use the brace in the correct way and for the required time is the most common cause of recurrence! You need to emphasize this to the parents.
- The brace needs to be put on immediately after the last casts are removed.



## 2. Bracing time frame

The following management is a recommendation for children with corrected Congenital Clubfoot and no signs of relapse. Every child's condition should be checked well for the decision of the suitable bracing time.

- Bracing time for the “younger child”(= not free walking before treatment start)

### \*) Start bracing under 9 months of age:

1. Fulltime (except bath)	= 23 hours a day:	3 months
2. Monthly reduced time	= 20-22 hours a day:	1 month
	= 18-20 hours a day:	1 month
	= 16-18 hours a day:	1 month
3. Night and nap time	= 14-16 hours a day:	several months until free walking
4. Night time	= 12-14 hours a day:	till age 4-5

### \*) Start bracing over 9 months of age:

1. Most time	= 18-20 hours a day:	2 months
2. Reduced time	= 16 hours a day:	3-4 months
3. Night time	= 12-14 hours a day:	till age 4-5

- Bracing time for the “older child”(= free walking before treatment start)

### \*) Start bracing under 4 years of age:

1. Most time	= 16-18 hours a day	3-4 months
2. Night time	= 12-14 hours a day	till age 5

### \*) Start bracing above 4 years of age:

1. Night time	= 12-14 hours a day	1 year
---------------	---------------------	--------

## 3. The Abduction Brace

- The brace needs to have both shoes attached to a bar in order to prevent a recurrence. An AFO (Ankle Foot Orthotic) is not enough - please don't try! There are many different types of braces available.
- Children should not be encouraged to stand or “walk” in this brace. The brace is not designed for this purpose.

- Abduction (or External rotation) and Dorsiflexion

- \*) Bilateral Clubfoot:

- For the “younger child” (= not free walking before treatment start):  
Both feet in 70° Abduction and 10°- 20° Dorsiflexion
    - For the “older child” (= free walking before treatment start):  
Both feet in 40°-60° Abduction and 10°-20° Dorsiflexion

- \*) Unilateral Clubfoot:

- For the “younger child” (= not free walking before treatment start):  
Clubfoot in 70° Abduction and 10°- 20° Dorsiflexion.  
Normal foot in about 40° Abduction and 10-20° Dorsiflexion.
    - For the “older child” (= free walking before treatment start):  
Clubfoot in 40°-60° Abduction and 10°- 20° Dorsiflexion.  
Normal foot in about 40° Abduction and 10- 20° Dorsiflexion.

- \*) For children with Clubfoot having hypermobile joints, low muscle tone and developed excessive Heel Valgus and External tibial torsion after correction:  
Both feet (Clubfoot and/or normal foot) in 30°-40° Abduction and 10°-15° Dorsiflexion.

- \*) Atypical Clubfoot:

- Clubfoot in 20°-30° Abduction and 0°-15° Dorsiflexion in the beginning. Later when the foot looks more normal, Abduction may be possible to change to 40°-50°.

- \*) Clubfoot associated with other defects (e.g.: Arthrogryposis, Myelomeningocele):

- The position needs to be individually arranged according to the situation. Children with neurological defects may need an additional AFO (Ankle Foot Orthotic).

- Length of the bar:

- Distance from one shoe heel to the other should be about the width of the child's shoulders.

#### **4. How to put the brace on**

- Make sure the skin is clean and very dry before putting the brace on.

- Put the brace on by first fitting the most difficult foot (Clubfoot if unilateral). Gently push the foot in Dorsiflexion and then push the heel into the brace first. Keep the foot in a good position. First close the inside strap and then close the outside straps of the shoe. Then fit the other foot.

- Make sure that the heel is properly placed in the brace. Use the inspection holes to ensure that this happens.
- Show the parents how to put the brace on and encourage them to help their child to get used to the brace (singing, playing and kicking the feet simultaneously...).

#### **5. Ordering of the brace**

- Measure the length of the soles of the child's feet and order the brace on the day you perform the tenotomy. If a tenotomy is not required, order the brace about 3 weeks before it is needed.
- A bigger size needs to be ordered, when the toes are curled over the edge of the shoes.
- Be very exact when you order the brace. The following information should be provided:
  - a) Whether bilateral or unilateral clubfoot.
  - b) The exact length of the soles of both feet.
  - c) Specify for every foot how much Abduction and Dorsiflexion is required.

## **6. Problems with the bracing**

- **The child's heel cannot be placed properly in the brace and/or the foot easily slips out of the brace** (even though the shoe is closed tight):
  - The Dorsiflexion may not be sufficient: Correct it with a series of casts and then consider another tenotomy of the Achilles tendon if sufficient Dorsiflexion has not been obtained.
  - Some Atypical Clubfeet (this is very rare) are not easy to hold in a brace: Try to adjust the brace by applying soft pads at the upper rim of the heel counter or make a special brace.
- **The child's foot has a sore or blister.**
  - The brace may be too big or too small: Try to adjust the brace by applying a soft pad in the brace or order a suitable size.
- **The child fights the brace and cries without any apparent reason.**
  - This may be caused by the parents removing the brace in response to the child's crying. Emphasize that they have to use the brace consistently to make the child compliant. Don't tolerate intermittent usage of the brace.
  - If the behavioural problems start after 2 years or more of sleeping time bracing and the feet look fine you can consider stopping the bracing but regular check ups are required every 3 months.
- **The bar of the brace is bent wrongly.**
  - Tell the parents the child should never stand with the brace on. Bend the brace back to the right position.

## **7. Check up timetable since the bracing phase**

- Make sure to organize the check ups according to the suitable bracing schedule and individual situation (e.g.: problem with brace compliance, pressure sores).
- Always tell the parents, that they should return immediately if a foot turns back, if they discover a pressure sore or if the brace gets too small or is broken.
- After each check up, make a new appointment with the parents for the next check up. Document it for yourself ([Appendix 3](#)) and write it down for the parents ([Appendix4](#)).
- **Timetable guideline**
  - 1<sup>st</sup> check up: 1 week after the bracing started.  
Check especially on brace compliance.
  - 2<sup>nd</sup> check up: 1 month later.  
The child should be adjusted to the brace.
  - 3<sup>rd</sup> check up: 1-3 months later depending on when bracing time should be reduced.
  - Checks in the 1<sup>st</sup> bracing year: At least every 3 months if no brace time change.  
Organize check ups according to the expected brace time changes.
  - Following checks in the bracing phase: Every 3-6 months.
  - Checks after bracing phase finished: Once a year until skeletal maturity.

# **RECURRENCES**

## **AND THEIR MANAGEMENT**

After Clubfeet are fully corrected and the child is in the bracing phase it is possible that feet will relapse. In general the younger the age of the child the higher the risk for relapse. A relapse after the age of 6 in an early treated child is rare if there is no other defect associated with Congenital Clubfoot.

The early recognition of a recurrence followed by correction of the relapse is important to continue to obtain a good result.

### **1. Cause of recurrences**

The pathology that initiated Congenital Clubfoot is also responsible for recurrences. As mentioned earlier, etiological factors for the development of the deformity seem to be active for several years.

### **2. Reasons for recurrences**

#### **a) Failure to wear the brace**

Failure to wear the brace properly: more than 80% of recurrences.

Proper wearing the brace: low percentage of recurrences.

#### **b) Failure in the treatment**

1. Not enough Abduction has been achieved, so the Navicular displacement was not fully corrected.

2. Not enough Dorsiflexion has been achieved.

#### **c) Possibly a few cases of “too” severe fibrosis in muscles, fasciae, ligaments and tendons in the posterior and medial aspects of the foot?**

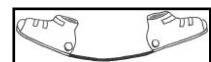#### **d) Associated defects**

Arthrogryposis, Myelomeningocele or other neurological defects may have a strong impact being an extra force supporting a relapse.

### **3. Prevention of recurrences**

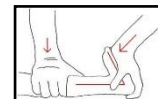
#### **a) Correction of 70° “Hyper abduction” in the “younger child”.**

#### **b) Strict bracing according to the bracing protocol.**



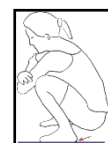#### **c) Stretching of the Gastrocnemius muscle.**

Recommendation: Stretching for 2 minutes before putting the brace on (done by parents).



#### **d) Squatting with heels on the floor stretches the Tibialis posterior muscle.**

Recommendation: Squatting 2 minutes a day (done by parents).



#### **e) Physiotherapy**

Different therapy methods and techniques on neurophysiological basis can be used to facilitate active movements of the feet and help to integrate the feet in physiological movement patterns of the whole body.

## **4. Kinds of recurrences and their treatment**

### **a) Varus recurrence**

1. Heel in Varus.

It can be clearly seen in the standing child while watching from the back.

**Treatment:** - **Manipulation + Casts**

- **Followed by Bracing + Stretching + Physiotherapy**

1. Manipulation and about 1-3 plaster casts for 1-2 weeks.
2. After correction back to bracing:
  - a) For a child who is not walking: Start again with 3 months fulltime bracing.
  - b) For a child who is walking: Start with 2 months 16-18 hours per day bracing.
3. Daily stretching of the Gastrocnemius muscle and squatting done by the parents. Physiotherapy in addition.

### **b) Equinus recurrence**

1. Less Dorsiflexion.  
Later it may develop Heel Varus, often some Adduction; Cavus rarely recurs.
2. Child walking away: early heel rise.  
Child walking toward: maybe weight bearing outside of the foot with Heel Varus.
3. X-ray (not necessary) from lateral in most possible Dorsiflexion shows:  
- Not 90° of Tibia to Calcaneus.

**Treatment:** - **Manipulation + Casts**

- **Possibly Tenotomy + Manipulation + Cast**

- **Followed by Bracing + Stretching + Physiotherapy**

1. Manipulation and about 1-3 plaster casts for 1-2 weeks.
2. Possibly repeat of the tenotomy of the Achilles tendon followed by casting for 3-4 weeks.
3. After correction back to bracing:
  - a) For a child who is not walking: Start again with 3 months fulltime bracing.
  - b) For a child who is walking: Start with 2 months 16-18 hours per day bracing.
4. Daily stretching of the Gastrocnemius muscle and squatting done by the parents. Physiotherapy in addition.

\* If another relapse appears the procedure should be repeated.

\* If a third relapse occurs a Tibialis anterior transfer may be required (see next page).  
Earliest to perform about the age of 2 ½ years: X-ray must show the ossification of the Cuneiforme laterale.

### **c) Dynamic Supination (= Tibialis anterior muscle very active)**

1. Noticeable Supination. Typically occurs between 2-4 years of age. The foot can still be passively positioned with the heel in Valgus.
2. Child walking toward:  
Supination of the foot in the swing phase and bearing weight on the outside border of the foot in the stance phase.
3. Variable amounts of Dorsiflexion and Plantar flexion are possible.

**Treatment:** - **Possibly Manipulation + Casts**  
- **Possibly Tenotomy**  
- **\*Tibialis anterior transfer (TAT) + Cast**  
- **Followed by Bracing + Physiotherapy**

1. Possibly 2-3 times manipulation followed by plaster casts for 1-2 weeks to gain a better position of the foot for the TAT.
2. Possibly repeat the tenotomy of the Achilles tendon on the same day as the TAT is performed (if less than 10° Dorsiflexion).
3. Tibialis anterior transfer (TAT) followed by 6 weeks long leg cast.
4. After correction night time bracing. Physiotherapy in addition.

#### **REMARK: \*Tibialis anterior transfer (TAT)**

The Tibialis anterior muscle is a strong supinator. This is so, because the insertion of the muscle is at the medial part of the foot (Cuneiforme mediale and Metatarsal I). By transferring the tendon to the Cuneiforme laterale the muscle will not work as a supinator any more.

The age of the child to perform the TAT should be about 3-5 years. The earliest age is about 2 ½ years. The X-ray must show an ossification of the Cuneiforme laterale.

Details of this procedure with photos can be found at: Global-HELP Publication: "Clubfoot: Ponseti Management".

## **5. Emphasis on the parent's role**

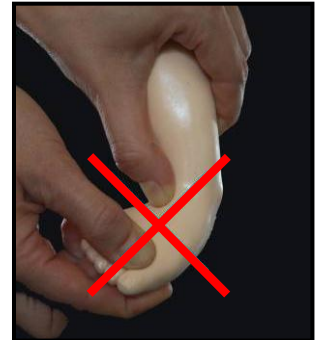
It needs to be remembered that the main reason for relapse is the failure to wear the brace as instructed. The parents need to be aware of their responsibility to follow the bracing protocol strictly and to advise the doctor if there are any difficulties with the brace (e.g. slippage of the foot, skin lesions) immediately after they appear. This helps to identify individual problems and make adjustments to the treatment.

# **COMMON ERRORS TO AVOID**

## **1. Pronation**

Pronation of the forefoot will make the deformity worse!  
It increases the Cavus by twisting the mid foot and forefoot.  
When pronating the foot the Calcaneus remains locked in Adduction under the Talus. The Inversion of the mid foot and heel Varus are corrected by abducting the foot under the Talus.  
Never pronate!

1.



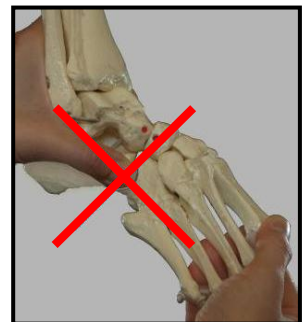## **2. External rotation in the ankle**

Trying to correct the foot Adduction by External rotation is a big error.  
It can cause a posterior displacement of the lateral Malleolus, an iatrogenic deformity. This doesn't happen when the foot is abducted with counter pressure on the lateral part of the head of the Talus.

## **3. Trying to abduct the foot by giving counter pressure on the lateral side of foot (near the Calcaneo-cuboid joint)**

3.

This error will block the Abduction of the Calcaneus and so the correction of the heel Varus. It arches the foot.



## **4. Failure to obtain full Abduction of the foot.**

The foot needs to be fully corrected. Otherwise a relapse is likely.  
Aim for 70° Abduction ("Hyper abduction") in the "younger child" and 50°-60° Abduction in the "older child".

## **5. Short-leg cast**

Long leg casts with 90° Knee flexion in the "younger child" and 70° Knee flexion in the "older child" prevent the ankle and Talus from rotating.

## **6. Attempts to correct the Equines before Mid foot Inversion and Heel Varus are corrected**

This error may cause a rocker bottom deformity.

## **7. Failure to use the brace**

Most common cause of relapse.

# **THE PARENTS**

The role of the parents in achieving a good result of the Clubfoot treatment is very important. If parents fail to follow the instructions during the casting phase and especially during the bracing phase, problems will occur and a high probability of relapses is likely.

It is necessary to emphasize to the parents that their cooperation is important for a successful outcome in their child's treatment. Explain the different steps of the treatment to the parents, so that they understand the importance of the instructions given to them.

## **1. Before the treatment**

- At the first consultation, take time to talk to the parents!
- Give them an explanation of Congenital Clubfoot.
- Give them an overview of the Ponseti treatment and explain the different steps and timing.
- Emphasize the parent's responsibility in following the instructions in the treatment procedure.
- Tell them to bring a prepared bottle to feed the small child while putting a new cast on. For an older child ask them to prepare small snacks.
- Inform the parents that it is normal for the (especially older) child to struggle at different stages of the treatment.
- Give them the "Information for Parents" brochure ([Appendix 2](#)).

## **2. During the casting phase**

- Emphasize that while the child's feet are in the casts they have to be checked regularly for a good blood circulation.
- Emphasize that the casts need to remain dry.
- Emphasize that they should call or visit the doctor if there is any sign of a problem mentioned in the "Information for Parents" brochure ([Appendix 2](#)).

## **3. During the bracing phase**

- When starting the bracing phase emphasize the importance of the brace in maintaining the correction of the feet.
- Make it very clear, that the child needs time to adjust to the brace and will probably cry in the beginning. Reinforce: "Never remove the brace in response to crying - otherwise the child may cry more in the future".
- Show them how to fit the feet into the brace and the correct position for the heel.
- Give them the "Parent's instruction sheet" ([Appendix 4](#)) and fill in all instructions for them. You document the same information for yourself in the "Doctor's check up sheet" ([Appendix 3](#)).
- Encourage them to follow all instructions strictly.
- Make a new appointment for the next check up and document it ([Appendix 3+4](#)). Tell the parents to bring the "Parent's instruction sheet" ([Appendix 4](#)) with them for the next check up.
- Emphasize that they should call or visit the doctor if there is any problem with the bracing.

## **4. After the bracing phase**

- Encourage the parents to come to the regular check ups bringing the "Parent's instruction sheet" ([Appendix 4](#)).

# CONGENITAL CLUBFOOT

APPENDIX I

## ASSESSMENT AND TREATMENT RECORD

Date of initial exam: \_\_\_\_/\_\_\_\_/\_\_\_\_

Name: \_\_\_\_\_ Sex: \_\_\_\_\_ Date of birth: \_\_\_\_/\_\_\_\_/\_\_\_\_ Age: \_\_\_\_\_

Place of birth: \_\_\_\_\_ Hospital ( ) Clinic ( ) Home ( )

Mother's name and phone number: \_\_\_\_\_

Father's name and phone number: \_\_\_\_\_

Foster mother's name and phone number: \_\_\_\_\_

Home address: \_\_\_\_\_

Welfare Institute: \_\_\_\_\_

**(Previous) diagnosis:** \_\_\_\_\_

### **History:**

Pregnancy: \_\_\_\_\_

Delivery and Post Delivery: \_\_\_\_\_

Family history: \_\_\_\_\_

Previously treated at /by: \_\_\_\_\_

Treatment method: \_\_\_\_\_

### **Examination:**

Head: \_\_\_\_\_

Spine: \_\_\_\_\_

Shoulders/Upper arms: \_\_\_\_\_

Elbows/Forearms: \_\_\_\_\_

Hands/Fingers: \_\_\_\_\_

Hips/Upper legs: \_\_\_\_\_

Knees/Lower legs: \_\_\_\_\_

Right Foot: Clubfoot: ( ) \_\_\_\_\_

Left Foot: Clubfoot: ( ) \_\_\_\_\_

### **Development and additional details:**

---

---

---

---

---

---

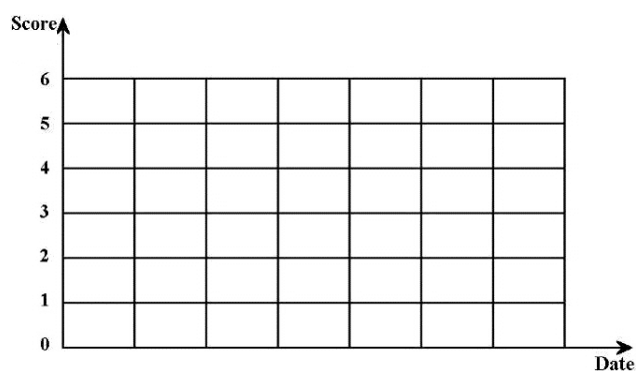
---

---

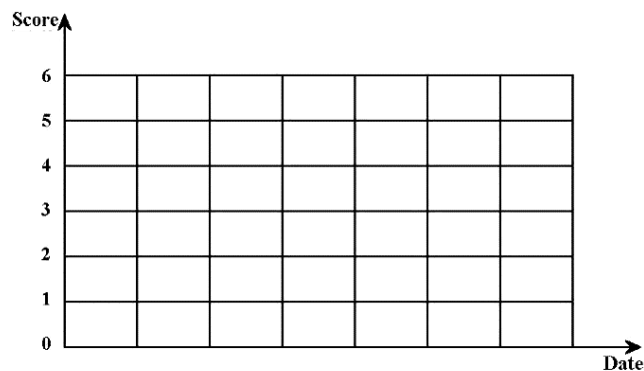
## Treatment graph recording during Ponseti treatment

<b>Date</b>												
<b>Age</b>												
<b>Foot</b>	right	left	right	left	right	left	right	left	right	left	right	left
Posterior Crease												
Empty Heel												
Rigid Equinus												
<b>HFCS</b> <span style="float: right;"><b>X</b></span> <small>Hind foot Contracture Score</small>												
Medial Crease												
LH Talus												
CLB												
<b>MFCS</b> <span style="float: right;"><b>Δ</b></span> <small>Mid foot Contracture Score</small>												
<b>TS</b> <span style="float: right;"><b>O</b></span> <small>Total Score</small>												
<b>TREATMENT *</b>												
<b>REMARKS</b>												

\***Key:** **MC** = Manipulation & Cast; **T** = Tenotomy of Achilles tendon; **AB** = Abduction Brace;  
**R** = Relapse; **TAT** = Tibialis Anterior Transfer; **PT** = Physical Therapy



**Right Foot**

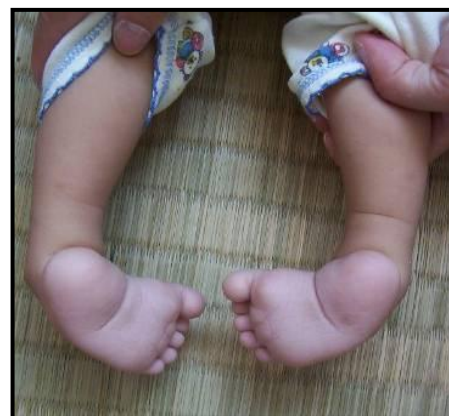
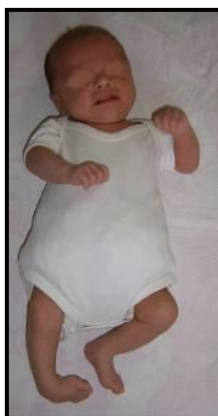
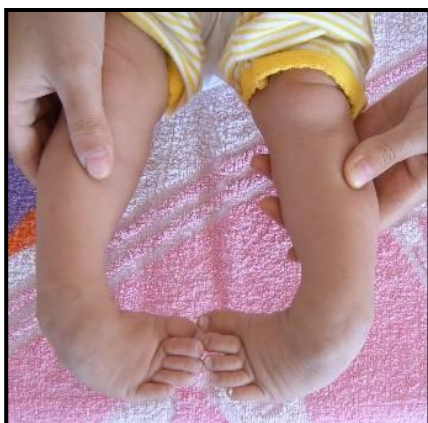**Left Foot**

### **ABOUT CLUBFOOT AND ITS TREATMENT**

The following information has been compiled to assist you in learning more about your child's condition, its treatment, and the important role you play in the treatment. It provides instructions, help and advice.

**Please note: Never hesitate to talk to the doctor, if there are any problems, questions or uncertainty about the instructions given to you.**



### **What is Congenital Clubfoot?**

Congenital Clubfoot is a developmental deformation and will be seen right from the baby's birth. Clubfoot can involve one foot or both feet.

During the development in the mother's womb a normal foot turns into Clubfoot. Tendons and ligaments in the back and inner side of the foot get thick and tight. Muscles develop shorter and smaller than normal. As a result, the back and inner parts of the foot are pulled together causing the foot to point downwards and twist inwards. The bones of the feet are therefore held in that abnormal position. The foot is turned, stiff and cannot be brought to a normal position by the child in a normal manner.

### **When to start the Clubfoot Treatment**

- **Soon after birth (~7-10 days):**
- **Not yet walking child:**
- **Walking child up to several years of age:**

**The best**  
**Very effective**

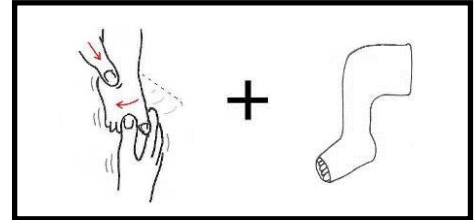
**Effective** in correcting all or much of the deformity. Depending on severity and other associated health issues, older children may require additional surgery.

# **OVERVIEW OF THE CLUBFOOT TREATMENT**

The description below is the normal procedure for young babies/children with Congenital Clubfoot. If your child is already older, or has other health problems in addition to Clubfoot, the treatment plan may differ.

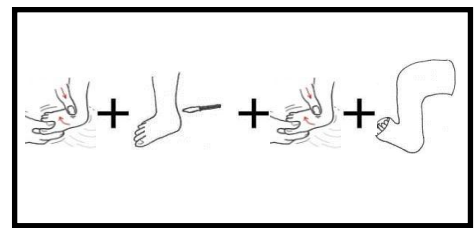
## **1. Manipulation and Cast for correction**

- Over a number of weeks, the foot is gently corrected by manipulating the bones into the right position.
- After every manipulation, the foot and leg are put into a plaster cast for 5-7 days to maintain the position in order to stretch the tight ligaments, joint capsules and tendons.
- This procedure will be done for about 4-6 times.  
A more severe clubfoot may need more casts.



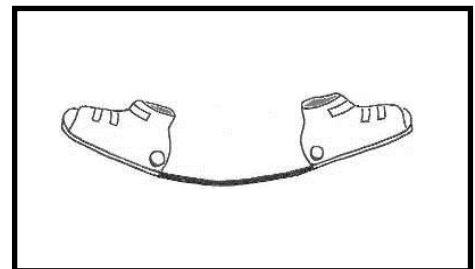
## **2. Manipulation, Cutting of the Achilles tendon and Cast for correction**

- In most cases the Achilles tendon will be cut to complete the correction. This is done by using local anaesthetic and takes only a few minutes. The tendon repairs itself and in doing so, gives the foot the Dorsiflexion that it needs.
- The foot and leg are then cast again, with that cast staying on for 3 weeks.



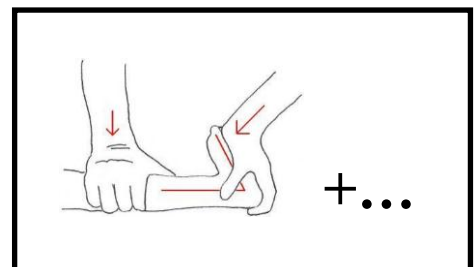
## **3. Bracing to maintain correction**

- When the last cast is removed, your child's feet will be put in a brace which should be kept on 23 hours a day, for 3 months. The brace is only taken off for bathing.
- After 3 months the bracing will be reduced over a period of time. At the end your child will only have to wear the brace for nights (12-14 hours a day) until the age of 4-5.
- The bracing is a critical part of the treatment. Even though the child's feet will look normal, if your child does not wear the brace, the feet will probably relapse.  
After the child reaches 7 years of age relapse is rare.



## **4. Physiotherapy**

- Different kind of exercises can be a helpful tool to maintain correction and support a good development of the child.
- Stretching or other exercises shown by the doctor or therapist can be done by the parents.



**To achieve the best result from treatment, the instructions need to be followed closely.**

## **INSTRUCTIONS AND HELPFUL ADVICE** **FOR THE CASTING PHASE**

Each time the casts are changed, come prepared with something for your child to eat or drink e.g. a bottle, or a favourite toy or book to keep her/him occupied while the new casts are applied.



### **1. After the 1<sup>st</sup> casts are applied**

Your child may be uncomfortable. The casts are quite heavy until they dry completely.

- Roll up a small towel and put it under the knees until the cast is dry.
- Distract your child by playing, singing, feeding or doing something that he/she enjoys.
- After a few hours or so, the child will get used to the cast.
- As soon as the casts are dry, allow the child do whatever he/she usually likes to do. Don't worry about damaging or dirtying the casts, they are strong. During humid weather ensure that the cast is fully dry and firm before allowing the child to crawl.
- When the child is sleeping, always roll up a towel and put it under the knees to relieve pressure on the heels.

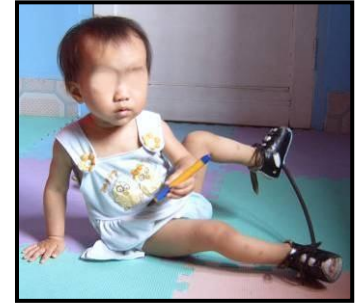### **2. While the casts are on**

- Keep the casts dry. Never use water to clean the cast, just wipe off any dirt.
- In winter, socks can be worn over the dry casts to keep them clean or to keep your child's toes warm.
- Use diapers or a cloth to cover your baby's bottom, so the casts don't get soiled.
- You cannot bath your child while he/she has the casts on.
- To keep the child clean:
  1. Lay the undressed child on a towel.
  2. Wet your hands and lather them up with soap.
  3. Rub your child all over with soap.
  4. Rinse the soap carefully off with a cloth, but don't get casts wet.
  5. Dry the child with a towel and dress.
- Check your child's feet regularly.

Check your child's feet several times a day to make sure they are a normal colour and warm. Do this by pinching the toes and watching the return flow of blood. The toes will turn white and then quickly return to pink, if the bloods flow to the foot is good.
- Call your doctor if:
  - The toes don't return to their normal colour.
  - The toes are swollen.
  - The toes are white or purple or blue.
  - The skin at the edges of the cast becomes very red, sore, or irritated.
  - The cast is too tight.
  - The cast is cracked or no longer hard.
  - The cast gets wet and is no longer hard.
  - You notice a bad smell coming from inside the cast.
  - You cannot see the toes – call the doctor immediately.

## **INSTRUCTIONS AND HELPFUL ADVICE** **FOR THE BRACING PHASE**

When the baby is taken out of the final cast and placed into the brace, it can take 3 - 7 days to adjust. The discomfort comes from missing their “security cast” and also from not having the ability to kick the legs independently.



### **Never remove the brace in response to crying - the child needs to adjust!!!**

The first few days are critical to long term brace tolerance. If you remove the brace in the first few days, your child may learn that crying is an effective way to be free of the brace, and this may cause you a lot of trouble in getting your child to wear the brace effectively.

You also need to know, that failure to use the brace in the correct way and for the correct time is the most common cause of relapse!

Wearing of the brace needs to become a normal part of your child’s daily routine.

### **1. How to put the brace on**

- Make sure the skin is clean and very dry before putting the brace on.
- Never use lotions on any red spots on the skin; it may make the problem worse.
- Put the brace on, by first fitting the most difficult foot. Gently push the foot in dorsiflexion and then push the heel first into the brace. Keep the foot in good position. First close the inside strap and then the other straps of the shoe. Then fit the other foot.
- Make sure that the heel is properly placed in the brace. Use the inspection holes to ensure the heel is in the correct position. You must be able to see the heel through the holes in the shoes.
- Help your child to get used to the brace by playing with her/him and teaching her/him to kick both legs together in the brace.

### **2. Fulltime bracing (23 hours a day) for 3 months**

- Only take the brace off for a bath. But not more than 1 hour.

### **3. Reduced time down to night time bracing until age 4-5**

- Change from the fulltime to the reduced time bracing /night time bracing, only on Doctor's orders.
- Never let your child stand with the brace on.
- Do stretching exercise, if the doctor instructs you to do so.
- Give your child soft flexible shoes to wear for walking.
- Don't miss regular check ups, even if everything is going well. Always bring the brace for the check up!
- Your child's brace needs to be changed for a bigger size only when the toes are completely curled over the edge of the shoes.
- Never stop using the brace unless the doctor tells you to stop.

### **4. Common Problems**

- If your child's foot is slipping out of the brace, check that the shoe is closed tightly enough. If you cannot prevent the foot slipping out of the brace, see the doctor.
- If your child complains frequently, check to ensure that there is no sore or blister on the heel. If there is, see the doctor.
- If your child is removing the shoes:
  - a) Put socks on over the whole shoe. This will not always stop them, but it makes it harder for them to remove.
  - b) Continue to put the brace back on!
- If there is any relapse, see the doctor as soon as possible. Don't wait for the next regular check up.
- If the brace is broken, call the doctor, so a new brace can be ordered.

### **MORE INFORMATION AT:**

[www.global-help.org/publications/books/book\\_cfponseti.html](http://www.global-help.org/publications/books/book_cfponseti.html)

[www.uihealthcare.com/topics/medicaldepartments/orthopaedics/clubfeet/index.html](http://www.uihealthcare.com/topics/medicaldepartments/orthopaedics/clubfeet/index.html)

# DOCTOR'S CHECK UP AND INSRUCTION SHEET

APPENDIX 3

(Since Bracing Phase)

Child's name: \_\_\_\_\_ DOB: \_\_\_\_\_

Clubfoot: right: ☐ left: ☐

Date	Age of the child	Reason to see the child	Problems reported by parents	Check up results (All Pirani Scores on treatment record)	Relapse measures	Brace: Condition	Brace instruction for parents	Stretching instruction for parents	Squatting instruction for parents	Other instructions for parents	Physio therapy prescription	Next check
				Total Score: _____ ROM: _____ Heel position: _____ Active squatting: _____ Active standing: _____ Standing on toes: _____ Sanding on heels: _____ Walking: _____ Jumping: _____ Skin: _____ Length of feet: _____		Abduction: _____ Details: _____	Hours per day: _____ Details: _____	Times per day: _____ Minutes per Clubfoot: _____ When: _____	Times per day: _____ Minutes: _____ When: _____			
				Total Score: _____ ROM: _____ Heel position: _____ Active squatting: _____ Active standing: _____ Standing on toes: _____ Sanding on heels: _____ Walking: _____ Jumping: _____ Skin: _____ Length of feet: _____			Hours per day: _____ Details: _____	Times per day: _____ Minutes per Clubfoot: _____ When: _____	Times per day: _____ Minutes: _____ When: _____			
				Total Score: _____ ROM: _____ Heel position: _____ Active squatting: _____ Active standing: _____ Standing on toes: _____ Sanding on heels: _____ Walking: _____ Jumping: _____ Skin: _____ Length of feet: _____			Hours per day: _____ Details: _____	Times per day: _____ Minutes per Clubfoot: _____ When: _____	Times per day: _____ Minutes: _____ When: _____			


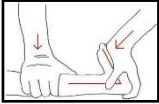

# PARENT'S INSTRUCTION SHEET

## (Since Bracing Phase)

**APPENDIX 4**

Child's name: \_\_\_\_\_ DOB: \_\_\_\_\_

Clubfoot: right: ☐ left: ☐

Date	Brace instruction 	Stretching instruction 	Squatting instruction 	Other instructions	Physiotherapy prescription	Next check
	Hours per day: _____ Details:	Times per day: ____ Minutes per Clubfoot: ____ When:	Times per day: ____ Minutes: ____ When:			
	Hours per day: _____ Details:	Times per day: ____ Minutes per Clubfoot: ____ When:	Times per day: ____ Minutes: ____ When:			
	Hours per day: _____ Details:	Times per day: ____ Minutes per Clubfoot: ____ When:	Times per day: ____ Minutes: ____ When:			
	Hours per day: _____ Details:	Times per day: ____ Minutes per Clubfoot: ____ When:	Times per day: ____ Minutes: ____ When:			
	Hours per day: _____ Details:	Times per day: ____ Minutes per Clubfoot: ____ When:	Times per day: ____ Minutes: ____ When:			
	Hours per day: _____ Details:	Times per day: ____ Minutes per Clubfoot: ____ When:	Times per day: ____ Minutes: ____ When:			
	Hours per day: _____ Details:	Times per day: ____ Minutes per Clubfoot: ____ When:	Times per day: ____ Minutes: ____ When:			
	Hours per day: _____ Details:	Times per day: ____ Minutes per Clubfoot: ____ When:	Times per day: ____ Minutes: ____ When:			

There are a small percentage of Clubfeet which are quite severe and known as Atypical or Complex Clubfeet. Usually atypical cases can only be identified after a few casts. It is often not obvious at the commencement of the treatment.

The medial ligaments and tendons stretch quite easily, but the Cavus and Rigid Equinus are difficult to correct. The Ponseti manipulation and casting technique then needs to be modified to achieve a good correction of these feet.

Only a mild Abduction of 20°- 40° (not 70°!) needs to be obtained. Attempts to gain more Abduction may cause even more Flexion in the Metatarsals and toes and Hyper abduction of the Metatarsals as well.

In addition the Hyper flexion of all Metatarsals has to be corrected also. The correction of the severe Equinus is difficult, but a Dorsiflexion of at least 5° should be achieved with the last cast. The Dorsiflexion normally improves after a few months.

### 1. Significant signs

1. Short and stubby foot (1.5 - 2cm shorter than normal foot, if unilateral case).
2. Soft skin and fluffy subcutaneous tissue.
3. Deep transverse crease in the sole of the foot.

All Metatarsals are in severe Plantar flexion. Severe Cavus.

4. Deep posterior crease above the heel. The heel in severe rigid Equinus and Varus.

Thick fat pad covers the under surface of the Calcaneus.

5. Navicular severe medially displaced. It may touch the medial Malleolus.

6. Anterior tuberosity of the Calcaneus bulges in front of the lateral Malleolus.

It can easily be mistaken for the head of the Talus (which is right above).

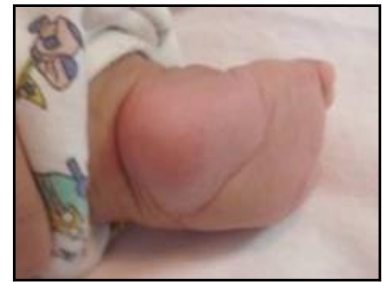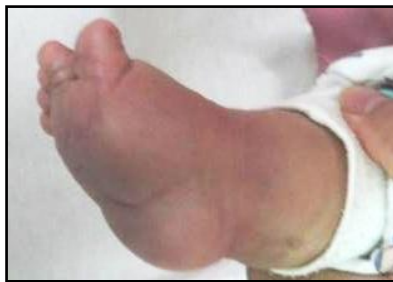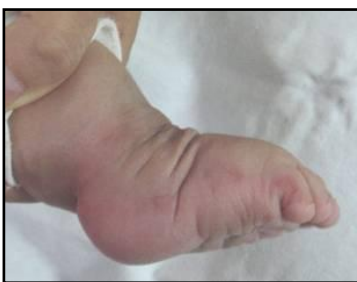7. Subtalar joint is very stiff.

Minimal motion is felt in the initial examination and possibly even after 2-3 casts.

8. First toe is short and hyper extended.

9. Calf muscles are small and bunched up in the upper third of the calf.

10. Achilles tendon is very wide, long and tight up to the middle third of the calf.



← Foot on the photos got already some treatment→

### 2. Precise identification of the head of the Talus and the Talo-calcaneo-navicular joint

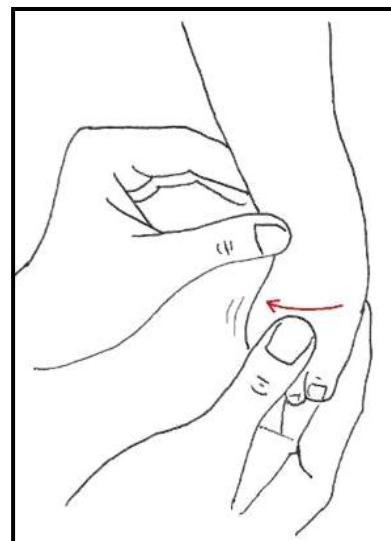
In these cases it is very important to localize the head of the Talus very well.

The head of the Talus is difficult to locate, because it is less prominent than the anterior tuberosity of the Calcaneus. The motion in the Talo-calcaneo-navicular joint is first minimal, but should be felt more after the 2nd or 3rd plaster cast.

### **3. Modification of the treatment**

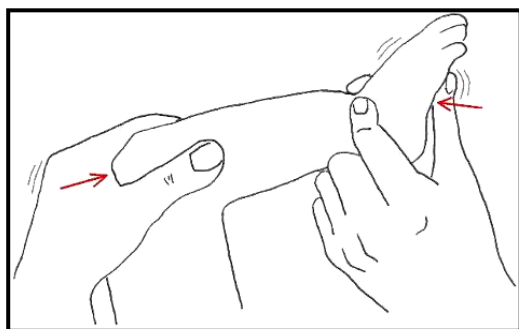
#### **a) Modified manipulation to correct the Mid foot Inversion and Heel Varus**

1. Put the thumb over the lateral aspect of the head of the Talus.
2. Put the index finger of the same hand over the posterior aspect of the lateral Malleolus.
3. Abduct the forefoot with the other hand while holding counter-pressure on the lateral aspect of the head of the Talus and posterior aspect of the lateral Malleolus.
4. Never abduct the foot beyond 40° (only about 30° is good).  
If you gain more Abduction, it is likely to produce a deformity with even more flexed Metatarsals and toes and Hyper abduction of the Metatarsals in the Lisfranc joint line. This is explained by the shortening and tightness of the deeper plantar muscles, especially severe fibrosis in the Quadratus plantae, which inserts into the tendon of the Long toe flexor muscle.

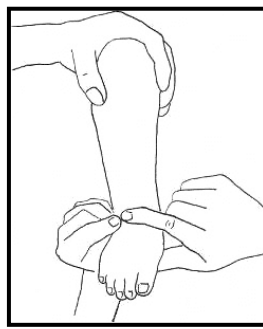


#### **b) Correction of the hyper flexed Metatarsals and the Rigid Equinus simultaneously**

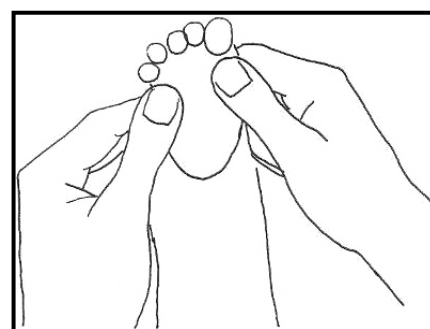1. Place both index fingers on each side of the head of the Talus. Put the thumbs on the sole of the foot, exactly on the heads of the 1st and 5th Metatarsals.
2. Move the mid foot in mild Abduction and the heel shouldn't be in Varus anymore. Push simultaneously the Metatarsals in Extension and the foot in Dorsiflexion whilst an assistant stabilizes the knee in Flexion. If Mid foot Inversion and Heel Varus haven't been corrected yet, don't push into Dorsiflexion in the ankle, but just focus on the correction of the Metatarsals and stretch the deeper plantar muscles. Be careful not to create a rocker bottom deformity.



Lateral View



Front View



Base (sole) View

#### **c) Prevent slippage of the plaster cast**

- Make sure to correct the hyper flexed Metatarsals (see b).
- Put a plaster cast on with 110° - 120° Knee flexion. Avoid too much plaster at the hollow of the knee and in front of the foot and ankle. Mould the plaster well!!!

#### **d) Percutaneous tenotomy of the Achilles tendon**

- Perform a tenotomy when you have achieved mild Abduction of 30° and the Hyper flexion of the Metatarsals has improved, but the Equinus is still very severe. If the foot often slips up in the cast you may perform a tenotomy earlier.
- Always cut the tendon 1, 5 cm above the posterior skin crease of the heel. This distance is necessary to avoid damage to the posterior tuberosity of the Calcaneus which is usually in a very high position.
- If necessary change the postoperative cast every 4-5 days till 5° Dorsiflexion (at least) and 40° abduction (at most) is achieved.

#### **e) Bracing and stretching**

The brace should only have an Abduction of about 30°- 40° in the beginning. Later, when the foot appears more normal, Abduction may be changed to 50°. The shoes must be well made to prevent slippage of the foot. I recommend stretching by the parents of the Gastrocnemius (Dorsiflexion with Knee extension) and the Tibialis posterior (squatting) to improve Dorsiflexion and prevent a relapse. Stretching of the deeper plantar muscles could be done as well.

#### **f) Managing a relapse**

Manipulation and casting again - change the casts every 1- 2 weeks. No need for a second tenotomy if you achieve 5° Dorsiflexion. I strongly recommend stretching by the parents of the Gastrocnemius (Dorsiflexion with Knee extension) and Tibialis posterior (squatting). I also recommend additional physiotherapy for some time.

#### **g) Overview of modifications:**

- Modification of the manipulation to correct Mid foot Inversion and Heel Varus: The index finger of the stabilizing hand should be placed behind the lateral Malleolus.
- Only 30°- 40° Abduction has to be achieved at the end, not more.
- Additional manipulation should be done to correct the hyper flexed Metatarsals and Rigid Equinus.
- Make sure to have 110°- 120° Knee flexion in the casts to prevent the foot slipping in.
- Perform the tenotomy of the Achilles tendon when 30° Abduction is achieved. Earlier tenotomy is needed, if the foot slips up often.
- 5° Dorsiflexion after the remove of the last cast are a satisfying result in some cases. Later the Dorsiflexion should improve.
- At bracing start, put the brace only in 30°- 40° Abduction. When the foot appears more normal you may go up to 50° Abduction. Make sure, that the foot doesn't slip up in the brace.
- Stretching of Gastrocnemius and Tibialis posterior and additional physiotherapy is recommended.

#### **4. Result to expect**

By using the described modified Ponseti treatment you can expect successful correction of the feet without the need for extensive corrective surgery. By keeping the correct bracing protocol, the foot's shape, length, motion of the subtalar joint and Dorsiflexion will usually continue to improve a few months after correction. The foot will appear more and more like a normal foot. It is possible that a plantar crease will still be seen after a few months and a minimal Cavus deformity might appear which can be passively corrected. The dorsiflexion can range from 10° - 25°.

## **ASSOCIATED WITH OTHER DEFECTS**

Neuromuscular diseases, chromosomal abnormalities, syndromes and other congenital abnormalities can be associated with Congenital Clubfoot. Some examples are Arthrogryposis Multiplex Congenita (AMC), Myelomeningocele (MMC), Larsen Syndrome, Diastrophic Dysplasia, Moebius Syndrome, Amniotic Band Syndrome, Metatarsus Adductus, Plantaris, limb deformities like Syndactyly, missing toes or extra toes.

The correction of Clubfoot associated with other defects may be more difficult, but never regard each case right from the beginning as a case for extensive surgery. In some defects you may need more casts for correction. In extremely difficult cases with no Dorsiflexion (no neutral position) after the tenotomy of the Achilles tendon you may apply a second cast after 4-5 days to achieve at least neutral position to 5° Dorsiflexion. Here are remarks for some defects you may encounter:

### **1. Arthrogryposis Multiplex Congenita (AMC)**

There is a wide variety in AMC. A lot of joints may have an extremely limited range of motion, but there are also cases that are “just” peripheral.

Expect more casts for correction in AMC. Be satisfied with 40-50° Abduction in younger children and 0°-10° Dorsiflexion in the ankle even after tenotomy, but never less than neutral position. Take care of following a strict bracing protocol and stretching. Prescribe intensive physiotherapy in these cases (for Clubfoot and deficits in other areas). The Abduction in the brace should be according to the achieved correction.

### **2. Myelomeningocele (MMC)**

There is also a variety in MMC. Extremely poor or no sensitivity may be found in feet, which is very important to check in every case. If the child is limited in feeling pain, it is not able to tell accurately, when there is too much pressure in a cast which can cause damage. A Poor blood circulation can cause skin damage in the cast as well. For these reasons, casts need to be applied and moulded very well and more padding over risky areas for pressure sores may be used.

Aim only for 40°-50° abduction in younger children and be satisfied with 5°-15° dorsiflexion. If 15° dorsiflexion has been achieved, there is no need for tenotomy. Especially in children with very low or no muscle activity in the foot don't get into too much Abduction and Dorsiflexion. Depending on the MMC severity, these children often need orthotics in addition.

### **3. Metatarsus Adductus**

When Clubfoot is combined with Metatarsus Adductus, the foot should be treated the same way as Clubfoot, but attention should be put on being sure that the adducted Metatarsus is corrected. If there is only Metatarsus Adduction present (which has no Equinus in the ankle joint!), don't treat it like Clubfoot. In Metatarsus Adductus manipulation can be done by giving counter pressure above the Calcaneo-cuboid joint followed by plaster casts for correction.

## **CLUBFOOT DEFORMITY AFTER EXTENSIVE SURGERY**

Insufficient corrected or relapsed Clubfoot after extensive surgery (posteromedial release) can be treated with Ponseti method as well. In a foot with extensive surgery in the medial part the foot is weakened. Therefore it is important to correct in less Abduction to prevent a Plano Valgus.

**RELATING TO THE PONSETI METHOD**

**GLOBAL HELP: Publications free to download:**

**Treatment Of Congenital Clubfoot Using The Ponseti Method: Workshop Manual**

[www.global-help.org/publications/books/book\\_clubfoottreatmentmanual.html](http://www.global-help.org/publications/books/book_clubfoottreatmentmanual.html)

**Clubfoot: Ponseti Management:**

[www.global-help.org/publications/books/book\\_cfponseti.html](http://www.global-help.org/publications/books/book_cfponseti.html)

**Clubfoot: Ponseti Management (Poster):**

[www.global-help.org/publications/books/book\\_cfponsetiposter.html](http://www.global-help.org/publications/books/book_cfponsetiposter.html)

**Ponseti Clubfoot Management: Teaching Manual For Health-Care Providers In Uganda:**

[www.global-help.org/publications/books/book\\_ponsetiuganda.html](http://www.global-help.org/publications/books/book_ponsetiuganda.html)

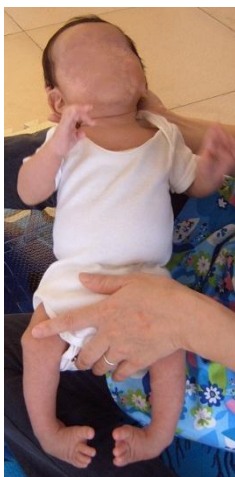**University of Iowa - Ponseti Clubfoot Center:**

[www.uihealthcare.com/topics/medicaldepartments/orthopaedics/clubfeet/index.html](http://www.uihealthcare.com/topics/medicaldepartments/orthopaedics/clubfeet/index.html)

**Ponseti International Association:**

[www.ponseti.info](http://www.ponseti.info)

**TREATMENT EXAMPLES**



before



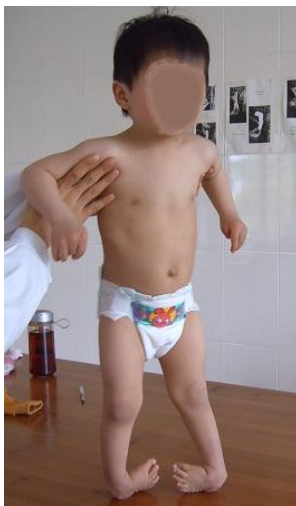after



before



after



before



after



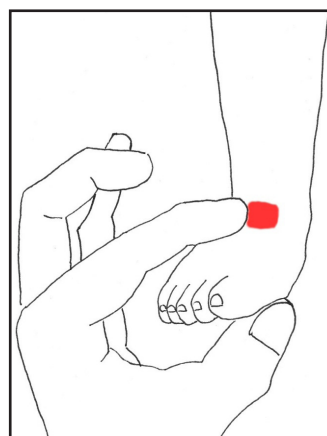
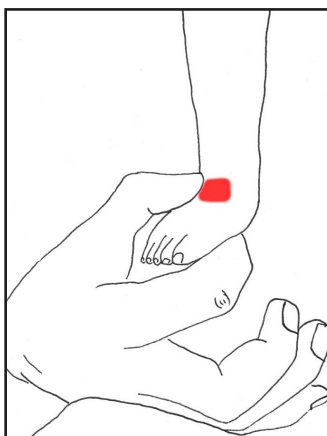
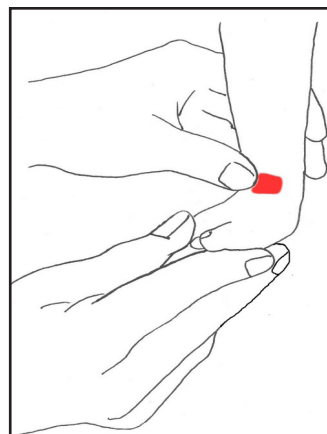
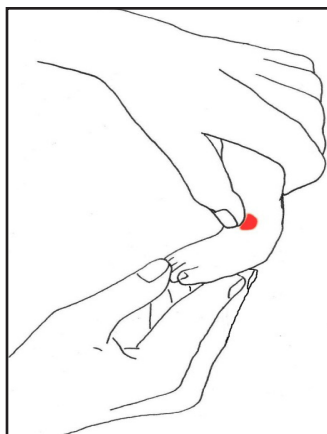
before



after

This Manual serves as a solid and practical guide for medical practitioners using the Ponseti technique to treat Congenital Clubfoot.

With easy-to-understand language and numerous drawings, the Manual helps to get the hand-positions for manipulation and casting just right.



Copyright © 2011 Global HELP Organization  
Originally published Iris Lohan (Copyright © 2011)  
Dimensions: 8.5" x 11.0"

ISBN 978-1-60189-115-0



9 781601 891150



GLOBAL HELP  
HEALTH EDUCATION USING LOW-COST PUBLICATIONS

WWW.GLOBAL-HELP.ORG